



Original article

Influence of odontogenic cysts on immune system – cytometric analysis of T lymphocytes subpopulation

Mansur Rahnama¹, Izabela Jastrzębska-Jamrogiewicz¹, Rafał Jamrogiewicz¹, Janusz Kocki²

¹ Chair and Department of Oral Surgery, Medical University in Lublin, Poland

² Department of Clinical Genetics, Medical University in Lublin, Poland

ARTICLE INFO

Article history

Received 23 September 2016

Accepted 6 June 2017

Available online 16 June 2018

Keywords

Odontogenic cyst

Lymphocyte T

Flow cytometry

Lymphocytosis

Doi

10.29089/2017.17.00046

User license

This work is licensed under a Creative Commons Attribution – NonCommercial – NoDerivatives 4.0 International License.



ABSTRACT

Introduction: Cysts are one of the most common lesions found in the stomatognathic system. Cysts cause not only bone defect but may also cause systemic complications.

Aim: Aim of the study was to investigate influence of odontogenic cysts on immune system.

Material and methods: 45 patients participated in the study. The study groups consisted of 15 patients with radicular cysts (IC) and 15 patients with dentigerous cysts (DC). The control group (C) consisted of 15 healthy patients. Blood, saliva and sacs of cysts were analysed with use of flow cytometry technique in order to assess number of T lymphocytes.

Results and discussion: Ratio of T lymphocytes in blood and saliva differed between groups. Analysis of cyst's sacs showed significantly higher number of T cells in radicular cysts.

Conclusions: The study has shown that odontogenic cysts have influence on immune system. T cells play important role in the process of odontogenic cysts' development. Research stresses how important is fast detection and treatment of cysts, not only in term of local but also systemic complications.

1. INTRODUCTION

Cysts are one of the most common lesions found in the stomatognathic system (Figure 1). This is due to the presence of numerous epithelial remnants from the developmental period. Cysts are difficult to detect, because in most cases, clinical symptoms occur when the size of lesion is large. An important aspect of late diagnosis, beside of significant losses of bone or facial deformities, is the possibility of malignant transformation in ameloblastoma or carcinoma.¹ An important and still not fully explored issue, is the impact of local, limited lesions, such as cysts, on the homeostasis of entire organism, especially the status of immune system, which has a role in the process of cysts' formation.

Depending on the type of cyst, the process of lesion formation has different character. Inflammatory cysts, which constitute about 84.5% of all odontogenic cysts, arise from the activated by infectious stimuli Malassez cells.² Ethio-pathogenesis of dentigerous cysts, which are odontogenic developmental cysts, is related with the epithelium surrounding erupting or impacted tooth. The process of cyst development results from pathological degeneration of follicle epithelium leading to squamous metaplasia.³ There are three theories of ethio-pathogenesis of dentigerous cysts. The expansion of space between the tooth germ and germ

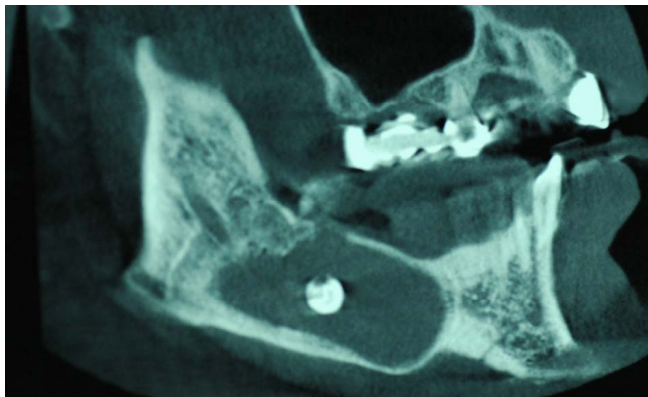


Figure 1. CBCT of odontogenic development cyst formed around impacted tooth.

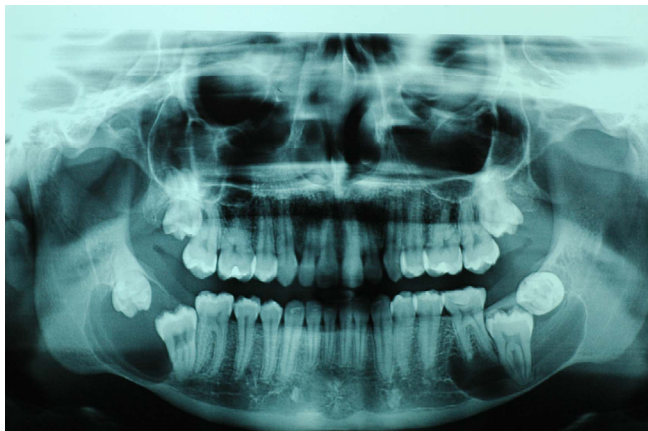

Figure 2. CBCT of odontogenic development cysts formed around impacted teeth in mandible.

sac, leading to the formation of cyst, may result from the pressure on vessels occurring during the tooth eruption. The pressure may lead the blockade of venous return and accumulation of fluid and reduction of follicle's epithelium. Second theory suggests that, epithelium surrounding tooth germ combines with remnants of inflammatory radicular cyst of primary tooth. Remnants of radicular cysts after combining with follicle sac lead to transformation to pathological dentigerous cyst. Third theory suggests, that epithelium surrounding tooth germ transforms after stimulation by bacteria from local inflammation in periapical region of primary root.⁴

T lymphocytes are responsible for the immunological answer of organism to pathological stimuli. T lymphocytes are important part of both, humoral and cell-mediated immunity. Immunological reaction with high activity of type 1 T helper lymphocytes (Th1) is associated with high concentration of interleukins (IL) IL-2, IL-12, tumor necrosis factor (TNF) alpha and high activity of osteoclasts.⁵ Th1 lymphocytes activate macrophages and CD8 lymphocytes. Th1 lymphocytes stimulate lymphocytes B, which leads to production of immunoglobulins, particularly IgG, which mediates bacteria opsonization and phagocytosis.⁶ In immunological reaction involving Th2 lymphocytes, high concentration of interleukins 4, 5, 6, 10 and 13 can be observed. Th2 lymphocytes have chemotactic effect on mast cells and eosinophils. Th2 response is also associated with increased antibody secretion by activated plasma cells. Th1 response is more characteristic for the initial inflammatory lesions, such as granulomas. Chronic changes are characterized by a predominance of Th2 response.

2. AIM

Thorough analysis is required, in order to allow recognition of systemic threats arising from the presence of odontogenic cysts. Aim of the study was to investigate influence of odontogenic cysts on immune system. Study was designed to examine whether lymphocytes T have a role in development of odontogenic cysts and if local lesion significantly influence status of whole immune system.

3. MATERIAL AND METHODS

The study got approval of Bioethics Committee in Lublin (consent number KE-0254,162,2012 and KE-0254/147/2014). The study was carried out in accordance with the ethical principles contained in the Declaration of Helsinki. The study involved 45 patients. The study groups consisted of 15 patients with radicular cysts (IC), and 15 patients with follicular cysts (DC). The control group (C) consisted of 15 healthy patients. All patients gave voluntary consent in writing to participate in the research.

Patients were qualified for further phases of the study after taking radiographs of the stomatognathic system (panoramic X-ray). Changes were asymptomatic. Patients

enrolled in the study, had no general diseases. Patients had no addictions and did not receive any medicaments on constant basis.⁷ Patients during last 3 months have not undergone any infections. During the clinical examination state of the oral mucosa, presence of any pathological lesions, dental status, oral hygiene and periodontal status were evaluated. The presence of dental plaque on the approximal surfaces of teeth was evaluated in order to determine approximal plaque index (API). Examination of periodontium enabled the assessment of the community periodontal index of treatment needs (CPITN) and sulcus bleeding index (SBI).

Patients selected for further tests, had no acute or exacerbated chronic periodontal disease. The maximum level of the SBI in patients qualified for further examination was 25%, while the maximum level of CPITN was 3 (grade 3 stands for depth of pockets between 3.5 mm and 5.5 mm). The study excluded patients with the presence of periodontal pockets deeper than 5 mm. Patients with periodontal calculus were subjected for oral hygienisation and reassessed 14 days after completion of periodontal treatment. Patients evaluated for laboratory tests had no pathological lesions located within the oral mucosa. The threshold for qualification in terms of API was 39%, which corresponds as an optimal or good oral hygiene.

Diagnostic material (blood and saliva) was collected from patients in fasting state. Non-stimulated saliva was obtained. Blood was drawn from a cubital vein. Sacs of enucleated cysts were put into saline. Obtained material was immediately transported to the laboratory of Department of Clinical Genetics of Medical University in Lublin.

Navios flow cytometer (Beckman Coulter) was used to analyze lymphocytes in venous blood and saliva. Saliva was diluted in PBS in a ratio of 1 : 9. The solution was centrifuged for 10 minutes at a speed of 1000 rpm. The precipitate was diluted with 1 mL phosphate buffered saline (PBS) and pipetted. The resulting solution was filtered twice (Beckman Coulter Filter Tip 30 microns); 100 mL of filtrate was collected and 10 μ L of anti-CD3 and CD45 Human APC EDC Human (Beckman Coulter) were added. The material was incubated for 15 minutes without accession of light. PBS (400 mL) were added and cytometric analysis was performed. In each sample 1000 cells were recorded. To the test-tube containing venous blood 10 μ L of anti-CD3 APC Human and CD45 Human EDC were added. Blood was incubated without accession of light for 15 minutes. Than 0.5 mL of OptiLyse reagent (Beckman Coulter) was added. The solution was incubated for 10 minutes. After incubation 500 mL of PBS added. The solution was centrifuged for 10 minutes at a speed of 1000 rpm. and incubated for further 5 minutes. The material was then subjected to cytometric analysis. 10 000 cells in each sample were recorded.

The sac of cyst was homogenized. Obtained suspension was diluted in PBS at a ratio of 1 : 9. The resulting solution was centrifuged for 10 minutes at a speed of 1000 rpm. The precipitate was once again diluted with 1 mL PBS. The resulting solution was filtered twice using filters (Beckman Coulter Filter Tip 30 microns); 100 mL of filtrate was col-

lected and 10 mL of anti-CD3 and CD45 Human APC EDC Human (Beckman Coulter) were added. The material was incubated for 15 minutes. Then 4 mL of PBS were added and cytometric analysis was carried out. In each sample 1000 cells were recorded.

Obtained data was analyzed with program Statistica 8.0. In order to determine the normal distribution of test results the W Shapiro–Wilk test was used. In the absence of normal distribution in order to compare results for three groups ANOVA Kruskal–Wallis rank test of multiple comparisons was used. The results of the statistical calculations are presented in the tables. The risk of inference error of the study is 5%, which means that the results were significant, if the *P* was equal or less than 0.05.

4. RESULTS

The highest average number of T cells in the blood was found in patients with inflammatory cysts, while the lowest in the group of healthy patients. The same tendency was observed in saliva. T cells were found both in radicular and follicular cysts. Higher count of T cells in cyst's sac was found in IC group when compared with DC group, however it should be noticed that T cells were present in both types of pathological lesions (Table 1).

On the basis of a Shapiro–Wilk test, hypothesis that the number of T cells has normal distributions in most assays has been rejected. For the comparison of lymphocytes T counts between particular groups nonparametric tests were used (ANOVA Kruskal–Wallis rank test and U Mann–Whitney test). In venous blood distributions of T cells in the particular groups differed significantly. Analysis of multiple comparisons test showed significant differences between the control group and the IC (higher number in IC group) and between group IC and DC (higher number in IC). The difference between the C group and the group of patients with development cyst was not statistically significant. In the saliva distributions of T cells in the individual groups differed significantly. Multiple comparison test showed significant differences between the C group and the IC group (higher number in patients with inflammatory cysts) and between the C group and the DC group (higher number in group of patients with development cysts). The difference between groups IC and DC was not statistically significant. By virtue of U Mann–Whitney test distributions of numbers of T cells in the sacs of the cysts showed statistically significantly differences between groups. In the group of radicular cysts T lymphocyte counts are higher than in the follicular cysts (Table 2).

5. DISCUSSION

Not only pathogens but also patient's immune system, which gives a response to a stimuli, are involved in the genesis of inflammatory cysts. The pathological stimulus leads

Table 1. The results of cytometric analysis of T lymphocytes (CD3+).

| Diagnostic material / Group | T lymphocytes (CD3+) | | | |
|-----------------------------|----------------------|--------|--------|-------|
| | <i>n</i> | M | SD | V, % |
| Blood | | | | |
| C | 15 | 470.3 | 546.2 | 116.1 |
| IC | 15 | 4391.9 | 3250.9 | 74.0 |
| DC | 15 | 914.3 | 1276.3 | 139.6 |
| Saliva | | | | |
| C | 15 | 121.6 | 403.0 | 331.4 |
| IC | 15 | 284.2 | 314.3 | 110.6 |
| DC | 15 | 233.3 | 215.3 | 92.3 |
| Sac of the cyst | | | | |
| IC | 15 | 32.3 | 33.7 | 104.2 |
| DC | 15 | 268.9 | 311.7 | 115.9 |

Table 2. Shapiro–Wilk test for T lymphocytes (CD3+), ANOVA Kruskal–Wallis test (with the test of multiple comparisons).

| Diagnostic material / Group | Shapiro–Wilk test | | | ANOVA Kruskal–Wallis test | | <i>P</i> for the test of multiple comparisons | | |
|-----------------------------|-------------------|--------|----------|---------------------------|----------|---|---------|----------|
| | <i>n</i> | W | <i>P</i> | H | <i>P</i> | C | IC | DC |
| Blood | | | | | | | | |
| C | 15 | 0.8034 | 0.0041 | | | – | <0.0001 | 0.6876 |
| IC | 15 | 0.8950 | 0.0797 | 21.40 | <0.0001 | <0.0001 | – | 0.0033 |
| DC | 15 | 0.5911 | <0.0001 | | | 0.6876 | 0.0033 | – |
| Saliva | | | | | | | | |
| C | 15 | 0.3027 | <0.0001 | | | – | 0.0040 | 0.0019 |
| IC | 15 | 0.7867 | 0.0025 | 14.72 | 0.0006 | 0.0040 | – | 1.0000 |
| DC | 15 | 0.8454 | 0.0150 | | | 0.0019 | 1.0000 | – |
| Sac of the cyst | | | | | | | | |
| | | | | U Mann–Whitney Test | | | | |
| | | | | U | | Z | | <i>P</i> |
| IC | 15 | 0.7785 | 0.0020 | 31.5 | | 3.3390 | | 0.0008 |
| DC | 15 | 0.8334 | 0.0102 | | | | | |

to activation of humoral and cell-mediated immunity. The humoral pathway is responsible for the control of extracellular microorganisms and toxins produced by these pathogens. Cellular immunity participates in the destruction of damaged or infected cells. T cells are essential in the course of these two processes. Particular subgroups of CD3+ cells support and induce a humoral immune response in order to start production of antibodies and regulatory cells inhibit the excessive inflammatory reaction. Present study was aimed to evaluate the involvement of CD3+ lymphocytes in the creation and development of odontogenic cysts.

During the process of qualification for laboratory test a lot of attention was put on the examination of oral cavity. In order to avoid disturbances of results by an active local inflammatory processes, patients with acute or advanced chronic periodontitis were disqualified from further tests. SBI, CPITN and API did not differ significantly between the groups. Naiff et al. demonstrated, using flow cytometry techniques, that chronic periodontitis results in increase in the number of leukocytes and immunoglobulins in the saliva, in comparison with a group of people with healthy periodontium.⁸ The results obtained in present study showed no

significant influence of API, SBI or CPITN on the number of lymphocytes which suggests that the process of clinical qualification was carried out properly and results were not modified by periodontal status. This fact allows to put forward thesis, while taking in consideration fact that patients enrolled for the study were generally healthy, without any infections or medications, that changes in the number of lymphocytes in the individual research materials are result of influence of odontogenic cyst on immune system.

The ethiopathogenesis of odontogenic cysts was a subject of interest of many researchers. Kontiainen and coworkers showed that the largest subpopulations of white blood cells which can be found in the wall of odontogenic cyst are lymphocytes.⁹ Matsuo and associates in their study, concerning the presence of immune cells in the odontogenic cysts, found that the number of T cells in the sac of the cyst was dependent on the size of lesion.¹⁰ Furthermore, authors demonstrated that in the symptomatic changes in the number of phagocytic cells was significantly higher than in asymptomatic changes. Results obtained during cytometric analysis presented in this study clearly indicated the involvement of CD3+ lymphocytes in the development

of odontogenic cysts. Comparative analysis showed that the number of T cells is significantly higher in radicular cysts when compared with developmental cysts. Although, it needs to be stated that lymphocytes T were found in both inflammatory and developmental cysts. The mechanisms involved in the pathological enlargement of dental follicle are not fully understood. One theory indicates that the epithelial cells of follicle are activated by pathological stimuli causing an inflammatory reaction. The results of present study showed significant presence of T cells in sacs of follicular cysts. It needs to be considered that all investigated changes were asymptomatic and were discovered incidentally during radiological examinations. This fact suggests a rejection of the hypothesis of infection of already preset follicular cysts, which would result in the onset of inflammatory infiltration. The results strongly suggest that the role of immune cells in the development of odontogenic follicular cysts is significant.

Saliva as a diagnostic material has been used by scientists for several years. The advantages of saliva, as a diagnostic material, are easy acquisition and lack of discomfort during collection of material, what is especially important in case of children or disabled patients. Unfortunately, the use of salivary gland secretion is associated with many difficulties. It is considered, that the content of substances which can be analyzed is approximately 1000 time lower than in serum.¹¹ In this study non-stimulated saliva was used. Non-stimulated saliva includes elements derived from the blood, which makes it reliable for test concerning the state of the whole organism. Flow cytometry, which is a very sensitive detection method, allows obtaining a very accurate evaluation of particular cell populations in saliva. Vidović et al. performed cytometric evaluation of particular populations of white blood cells in the saliva.¹² Authors demonstrated that saliva is dominated by polymorphonuclear cells, but there are also subpopulations of T and B lymphocytes or monocytes. The researchers evaluated the number of cells in the saliva of each patient three times and found that the results obtained in each measurement are compatible. Flow cytometric analysis performed in present study indicates that saliva can be successfully used for assessing subpopulation of T cells. Comparative analysis of saliva between groups showed that the number of T cells was significantly higher in the study groups when compared with the C group. The results obtained from saliva correlated with the results obtained during the analysis of venous blood, but the differences in the results of flow cytometric analysis of saliva are larger which makes them statistically significant. This suggests that the increase of CD3+ lymphocytes in the saliva may suggest the existence of an odontogenic cyst in the stomatognathic system.

In present study we wanted to evaluate the effect of odontogenic cysts on the status of immune system. This issue has not been broadly investigated in past. Anil et al. evaluated the presence of immune complexes in patients who were diagnosed with chronic periapical changes or odontogenic cysts.¹³ Obtained results showed that in the study group con-

centration of circulating immune complexes was significantly higher than in healthy subjects. It should be stressed that immune complexes can cause tissue damage not only in the area of their formation but also in the areas distant from the focal lesion. In present study number of CD3+ lymphocytes in blood serum was higher in study groups when compared with the C group, but the difference was high enough to be statistically significant only between the IC and C groups. Analysis of differences in the number of T cells between study groups revealed that in the group of radicular cysts number of CD3+ cells was significantly higher in comparison with the follicular changes. Okada et al. described the effect of periapical changes on the immune system of rabbits.¹⁴ Researchers discovered hypergammaglobulinemia which was increasing along with the duration of pathological process. Histopathological study carried out after the test showed the presence of early stages of endocarditis, hepatitis and glomerulonephritis. All these facts indicate how important is early detection and treatment of odontogenic cysts and how significantly they influence the human organism.

6. CONCLUSIONS

The saliva may be successfully used as diagnostic material for the study of immune cells and severity of local inflammatory reaction.

The results suggest that odontogenic cysts have significant impact on immune system of the organism.

T lymphocytes are involved in genesis of both radicular and follicular cysts.

Conflict of interest

All authors declare that there is no conflict of interest.

Funding

The study was funded by Medical University in Lublin.

References

- 1 Elzay RP. Primary intraosseous carcinoma of the jaws. Review and update of odontogenic carcinomas. *Oral Surg Oral Med Oral Pathol.* 1982;54(3):299–303. [https://doi.org/10.1016/0030-4220\(82\)90099-8](https://doi.org/10.1016/0030-4220(82)90099-8).
- 2 Tortorici S, Amodio E, Massenti MF, Buzzanca ML, Burruano F, Vitale F. Prevalence and distribution of odontogenic cysts in Sicily: 1986–2005. *J Oral Sci.* 2008;50(1):15–18. <https://doi.org/10.2334/josnusd.50.15>.
- 3 Tegginamani AS, Prasad R. Histopathologic evaluation of follicular tissues associated with impacted lower third molars. *J Oral Maxillofac Pathol.* 2013;17(1):41–44. <https://doi.org/10.4103/0973-029X.110713>.
- 4 Gondim JO, Neto JJ, Nogueira RL, Giro EM. Conservative management of dentigerous cyst secondary to primary tooth trauma. *Dent Traumatology.* 2008;24(6):676–679. <https://doi.org/10.1111/j.1600-9657.2008.00616.x>.

- ⁵ Fukada SY, Silva TA, Garlet GP, Rosa AL, da Silva JS, Cunha FQ. Factors involved in the T helper type 1 and type 2 cell commitment and osteoclast regulation in inflammatory apical diseases. *Oral Microbiol Immunol.* 2009;24(1):25–31. <https://doi.org/10.1111/j.1399-302X.2008.00469.x>.
- ⁶ Jankovic D, Liu Z, Gause WC. Th1- and Th2-cell commitment during infectious disease: asymmetry in divergent pathways. *Trends Immunol.* 2001;22(8):450–457. [https://doi.org/10.1016/S1471-4906\(01\)01975-5](https://doi.org/10.1016/S1471-4906(01)01975-5).
- ⁷ Koc-Gaşka M. Diagnostic pitfalls of tobacco smoking: The effect of nicotine addiction on the oral cavity – Literature review. *Pol Ann Med.* 2013;20(1):56–61. <https://doi.org/10.1016/j.poamed.2013.02.001>.
- ⁸ Naiff PF, Ferraz R, Cunha CF, et al. Immunophenotyping in saliva as an alternative approach for evaluation of immunopathogenesis in chronic periodontitis. *J Periodontol.* 2014;85(5):111–120. <https://doi.org/10.1902/jop.2013.130412>.
- ⁹ Kontiainen S, Ranta H, Lautenschlager I. Cells infiltrating human periapical inflammatory lesions. *J Oral Pathol.* 1986;15(10):544–546.
- ¹⁰ Matsuo T, Ebisu S, Shimabukuro Y, Ohtake T, Okada H. Quantitative analysis of immunocompetent cells in human periapical lesions: correlations with clinical findings of the involved teeth. *J Endod.* 1992;18(10):497–500. [https://doi.org/10.1016/S0099-2399\(06\)81350-6](https://doi.org/10.1016/S0099-2399(06)81350-6).
- ¹¹ Christodoulides N, Mohanty S, Miller CS, et al. Application of microchip assay system for the measurement of C-reactive protein in human saliva. *Lab Chip.* 2005;5(3):261–269. <https://doi.org/10.1039/b414194f>.
- ¹² Vidović A, Vidović Juras D, Vučićević Boras V, et al. Determination of leucocyte subsets in human saliva by flow cytometry. *Arch Oral Biol.* 2012;57(5):577–583. <https://doi.org/10.1016/j.archoralbio.2011.10.015>.
- ¹³ Anil S, Shanavas KR, Beena VT, Remani P, Vijayakumar T. Quantitation of circulating immune complexes in patients with chronic periapical lesions. *J Nihon Univ Sch Dent.* 1993;35(3):175–178. <https://doi.org/10.2334/jo-snusd1959.35.175>.
- ¹⁴ Okada H, Aono M, Yoshida M, Munemoto K, Nishida O, Yokomizo I. Experimental study on focal infection in rabbits by prolonged sensitization through dental pulp canals. *Arch Oral Biol.* 1967;12(9):1017–1034. [https://doi.org/10.1016/0003-9969\(67\)90156-2](https://doi.org/10.1016/0003-9969(67)90156-2).