



Original article

Propolis alcohol extract attenuates prostate specific antigen disorders and prostate necrosis induced by the cadmium toxicity in rats

Abdelkrim Berroukche, Mohamed Terras, Imane Denai

¹ *Laboratory of Water Resources and Environment, Biology Department, Faculty of Sciences, Dr. Tahar-Moulay University, Saida, Algeria*

ARTICLE INFO

Article history

Received 14 February 2017

Accepted 30 October 2017

Available online 30 January 2018

Keywords

Cadmium

Toxicity

Propolis

Prostate specific antigen

Doi

10.29089/2017.17.00003

User license

This work is licensed under a Creative Commons Attribution – NonCommercial – NoDerivatives 4.0 International License.



ABSTRACT

Introduction: Cadmium, heavy metal, is causing toxicity. Propolis is a natural product derived from plant resins collected by honeybees. Studies reported this substance is an antioxidant and antitumor.

Aim: The aim of this study is to assess the effects of the propolis alcohol extract (PAE) against the prostate specific antigen (PSA) disorders and prostate necrosis induced by the cadmium (Cd) toxicity in rats.

Material and methods: Parameters as body weight gain, blood PSA, blood Cd²⁺ and prostate tissue examination were performed in four groups of rats as follow: GR1 (controls), GR2 (administered orally with CdSO₄ at the dose 28 mg/kg BW), GR3 (exposed to CdSO₄ then treated orally with PAE at the dose 250 mg/kg BW) and GR4 (PAE/CdSO₄ in the same conditions). Experimental period was 35 days.

Results and discussion: Cadmium toxicity induced a decrease in body weight gain and an increase in prostate gland weight, blood PSA and Cd²⁺ levels. Cd also induced prostate necrosis in which it was noted a marked irregular acini and solid parenchyma. Whereas the treatment of animals with PAE revealed that body weight gain and blood PSA are low. Propolis increased preventive effects in rat's prostate in GR4 better than GR3. Propolis has beneficial effects and could antagonize Cd-induced prostate toxicity.

Conclusions: The results showed that propolis antagonized the harmful effects of CdSO₄. These findings showed that propolis could protect the human health through preventing the prostatic diseases.

Corresponding author: Abdelkrim Berroukche, Research Laboratory of Water Resources and Environment, Biology Department, Faculty of Sciences, Dr Tahar-Moulay University, 20000 Saida, Algeria. Phone: +213555972162.

E-mail address: kerroum1967@yahoo.fr, Abdelkrim.berroukche@univ-saida.dz.

1. INTRODUCTION

Since a long time, the toxicity of heavy metals generated an interesting debate. Metals are toxic at low dose and accumulate in living organisms. The urinary excretion of metals is less rapid than their absorption.¹ Cadmium (Cd) exposes human to toxicity risks through various means such as the ingestion of contaminated food and industrial use.² International Agency for Research on Cancer (IARC) classified Cd as a category I human carcinogen.³ However, studies suggested that the prostate is sensitive to Cd toxicity.^{2,4} Cd toxicity induces the oxidative stress and the synthesis of the reactive oxygen species (ROS).³ Prostate cancer is the second most diagnosed cancer of men.^{5,6} However, 90% of prostate cancer patients received androgen ablation therapy and chemotherapy that may decrease blood prostate specific antigen (PSA) and improve urinary symptoms. These therapies lead to adverse effects such as toxic death and strokes.^{7,8} Various plants and trees covering large areas in the Southwestern Algeria and are the main residence sites of honeybees (*Apis mellifera* L.). Majesty bees collect a natural resinous substance from buds and exudates of plants and to produce the propolis after mixed it with pollen and enzymes secreted by bees.⁹ Honeybees used propolis to smooth out the internal walls of the hive and as a protective barrier against their enemies.¹⁰ The local population of Southwestern Algeria used propolis as remedy against diseases. Studies revealed the anti-inflammatory, anti-oxidant and antimicrobial activities of propolis.^{10,11} Other works suggested the changes of chemical composition of propolis.^{12,13} Propolis is consisted of bioactive molecules such as: polyphenols, flavonoids and terpenoids. Its chemical composition is influenced by climatic, botanical and geographical factors.^{13,14} The Southwestern Algeria flora has a high biodiversity with many endemic plants. This could differentiate the composition of Algerian propolis compared to African and European propolis.^{13,15}

2. AIM

This study aimed to assess the preventive effects of propolis alcohol extract (PAE) against Cd toxicity induced at prostate gland in rats.

3. MATERIAL AND METHODS

3.1. Chemicals

Dimethyl sulfoxide (DMSO), ethanol (80%), cadmium sulfate (CdSO_4), formalin (10%), acetone, xylene, paraffin, toluene, distilled water, hymatoxylene, chloridric acid (HCl), lithium carbonate [$\text{Li}_2(\text{CO}_3)_2$], eosine were obtained from the Biology Department, Faculty of Sciences, Dr Tahar Moulay University, Saida, Algeria.

EDTA, murine monoclonal antibodies anti-PSA, conservatives, serum calf (5%), sodium azide (0.9 g/L), wash buffer (Tris 0.05 mol/L and Tween 0.05%), sodium chlorid (NaCl, 0.1 mol/L), 4-methyl-ombelliferyl phosphate (0.06 mmol/L),

diethanolamine (DEA, 0.62 mol/L) were purchased from the Laboratory Bio Merieux, France. The dose of CdSO_4 was 28 mg/kg BW (i.e. 1/10 of LD50, LD50 = 280 mg/kg BW).¹⁶

3.2. Preparation of PAE

Fifty grams of the resinous material of the Southwestern Algeria propolis (obtained from Rebahia area, province of Saida, located in Southwestern Algeria) was powdered and extracted with 600 mL of 80% (v/v) ethanol at 70°C for 35 minutes. After extraction, the mixture was centrifuged and the supernatant was evaporated to complete dryness at 40°C.¹⁷ The dried residue was kept at 4°C for the further use. Aqueous suspension of propolis was prepared in gum arabic suspension (1%), and orally administered to the animals for 35 days in a dose of 250 mg/kg.¹⁷

3.3. Animals

Male Wistar albino rats weighting 180–200 g were provided by the breeding unit of Pasteur Institute, Algiers. They housed under controlled conditions (25°C temperature and 12-hours lighting cycle) and received standard diet and water ad libitum during the study period. The study complies with the Guide for Care and Use of Laboratory Animals published by the US National Institutes of Health (NIH Publication No. 85–23, revised 1996) and approved by the Ethics Committee for Animal Experimentation at Faculty of Sciences, Saida University, Algeria.

3.4. Experimental design

Forty adult male rats were divided into four groups (10 rats in each group):

- (1) GR1 – animals received distilled water and standard diet, served as normal control (NC),
- (2) GR2 – animals received daily and orally CdSO_4 at a dose of 28 mg / kg BW,
- (3) GR3 – animals received CdSO_4 at 28 mg/kg and propolis alcohol extract (PAE) at a dose of 250 mg / kg BW,
- (4) GR4 – animals received PAE and CdSO_4 in the same experimental conditions.

3.5. Body and prostate tissue weight

We recorded initial and final body weights of male rats to measure weight body gains. After the sacrifice of animals, prostates were dissected out, trimmed off the attached tissues and weighed individually. Then, the organ/body weight ratio was measured. Specimens of the prostates were fixed immediately in formalin for histological study.

3.6. Blood PSA assay

After 35 days, animals were anesthetized (sodium pentobarbital 40 mg/kg BW), blood samples were obtained from hearts and allowed to clot for 20 minutes in laboratory temperature and then centrifuged at 3000 r/min for 10 minutes for serum separation. Serum-PSA levels were measured by mini VIDAS automate analyzer (Bio-Merieux, France). The method was the technique of enzyme-linked fluorescent assay (ELFA): it is an enzyme immunoassay ELISA ‘sand-

wich' in heterogeneous phase. Reading of the PSA values passes through two steps to a final detection by fluorimetry. Validation of results need a quality control performed for each kit VIDAS-PSA used.

3.7. Blood Cd²⁺ assay

The spectrophotometric analysis allowed carrying out the blood Cd²⁺ assay. We collected blood samples in EDTA tubes destined for analysis by the automate instrument (Abacus 4 Hematology Analyzer, Hungary).

3.8. Histological study

The rats were dissected to isolate prostate tissues. After draining the blood, prostate samples were excised, washed with normal saline and processed separately for histological observations. Initially, the materials were fixed in 10% buffered neutral formalin for 48 h and then with bovine solution for 6 h. Paraffin sections were taken at 5 mm thickness, processed in alcohol-xylene series. For light microscopy, semithin sections of prostate tissue were stained with alum haematoxylin-eosin and examined with an Olympus BH-2 light microscope and photographed with Sony DSC-W610 digital camera (Sony Corporation Konan, Minato-ku, Tokyo, Japan).

3.9. Statistical analysis

Results were expressed as mean \pm standard error of mean (SEM). Statistical analysis was performed with Sigmaplot version 11.0 software. ANOVA test was performed to evaluate if there were any statistically significant differences between treated and control groups.

4. RESULTS

Table 1 shows body and tissue weights and weight ratio of animals. Statistically significant body weight gain (%) was observed in animals treated with PAE according to curative and preventive methods (GR3 and GR4) which showed re-

spectively the values of 8.49% and 9.13% compared to control and experimental groups which respectively had 31.34% and 15.36%. However, no significant difference in prostate tissue weight was recorded in the groups treated with PAE compared to control and experimental animals.

An increased prostate weight, in rats treated with CdSO₄, explained the higher Cd levels in the prostatic cells (9.3 \pm 0.89 μ g/L) compared to the controls (0.02 \pm 0.01 μ g/L). Whereas, in animals treated with PAE (GR3 and GR4), prostate gland weight slightly decreased which blood Cd²⁺ levels were 1.36 \pm 0.29 μ g/L and 0.75 \pm 0.02 μ g/L, respectively (Table 1). These results elucidated curative and preventive effects of PAE, which inhibited the Cd accumulation and protected the prostate tissue from this toxic heavy metal.

Blood-PSA levels were significantly higher in rats treated with CdSO₄, which they showed 9.15 \pm 1.62 ng/mL as compared to controls (2.27 \pm 0.28 ng/mL). Whereas, we noted a significant decrease of blood-PSA in rats administrated orally with PAE (GR3 and GR4). The blood PSA concentrations were 4.69 \pm 0.48 ng/mL and 3.9 \pm 0.24 ng/mL, respectively.

In general, the prostate of the control rats consists of fibroblasts, connective tissue fibers and layers of smooth muscle cells surrounding acini lined by columnar epithelial cells (Figure 1A). Figure 1B shows the effect of oral CdSO₄ exposure on the incidence of proliferative lesions in the prostate. These proliferative lesions were exclusively intraepithelial hyperplasia without stromal invasion. Oval and irregular neoplastic glands associated with confluent solid zones accentuated the prostatic structures. Whereas in animals, exposed to CdSO₄ and then treated orally with PAE (Figure 1C), it was revealed slight dysplastic modifications in the ventral prostate acinar epithelium. The control acini showed a columnar monostratified epithelium, whereas the dysplastic acini manifested an irregularly enlarged epithelial lining with occasional polyploidy formations. Prostate glands, in rats treated with PAE and then administered with CdSO₄, had apparently normal cells with differentiated glandular structures and relatively little mitosis (Figure 1D).

Table 1. Effects of oral administration of cadmium sulfate and propolis for 35 days on the body and prostate weight, blood PSA and Cd²⁺ in male rats.

	GR 1 (Controls)	GR 2 (CdSO ₄)	GR 3 (CdSO ₄ / PAE)	GR 4 (PAE / CdSO ₄)
Body weight (g)				
Mean (\pm SEM)	223.16 \pm 9.87	167.26 \pm 4.49	190.33 \pm 2.83	176.65 \pm 2.79
Initial BW (\pm SEM)	192.30 \pm 8.60	158.32 \pm 4.73	180.42 \pm 1.39	168.60 \pm 2.79
Final BW (\pm SEM)	252.58 \pm 9.87	182.65 \pm 4.49	195.74 \pm 2.83	184.00 \pm 4.19
Body weight gain (%)	31.34 ^a	15.36 ^a	8.49 ^a	9.13
Prostate weight (g)				
Mean (\pm SEM)	0.24 \pm 0.02	0.84 \pm 0.04	0.66 \pm 0.12	0.60 \pm 0.43
Prostate/body weight ratio				
Mean ($\times 10^{-3}$)	1.07	5.02	3.46	3.39
Blood-PSA (ng/mL)				
Mean (\pm SEM)	2.27 \pm 0.28	9.15 \pm 1.62 ^a	4.69 \pm 0.48	3.9 \pm 0.24 ^a
Blood-Cd ²⁺ (μ g/L)				
Mean (\pm SEM)	0.02 \pm 0.01	9.3 \pm 0.89 ^a	1.36 \pm 0.29	0.75 \pm 0.02 ^a

Comments: a – statistically significant difference as compared with experimental controls (CdSO₄) ($P < 0.05$).

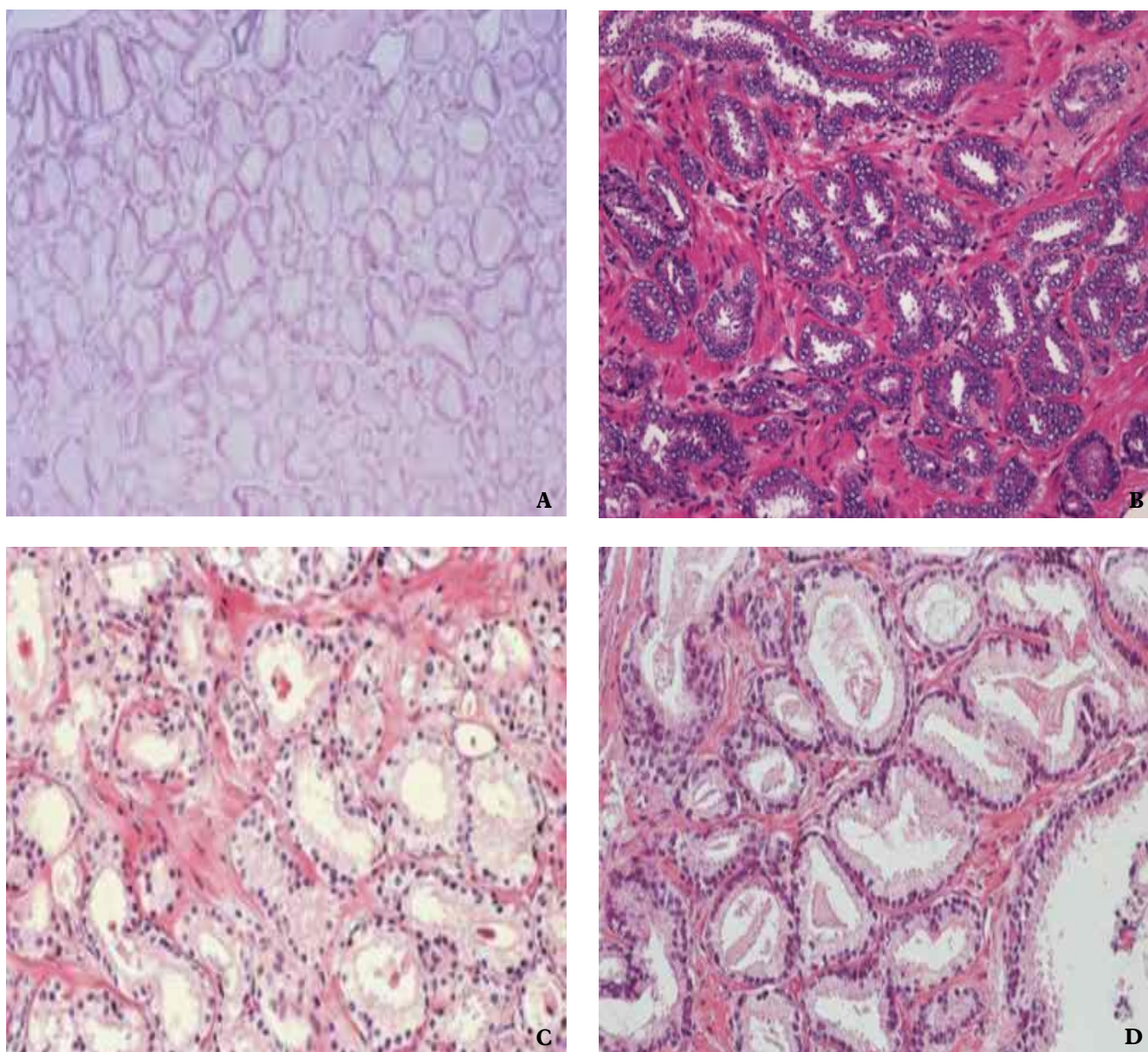


Figure 1. Effects of PAE on prostate tissue in rats exposed to CdSO₄ (H-E, magnification 10 × 40): A. Normal prostate gland in control rat. Differentiated acini and regular cell forms. B. Prostate tissue in rats exposed to CdSO₄. Irregular acini forms and necrosis tissues associated with solid parenchyma areas. C. Prostate tissue in rats treated in order with CdSO₄/Propolis. More or less irregular and angular acini and differentiated prostatic cells were observed. D. Prostate tissue in rats treated in order with the Propolis/CdSO₄. Regular acini forms with a less or more accentuated areas, without necrosis of prostate tissue were observed.

5. DISCUSSION

Studies provide evidence that propolis protects humans against cancer, and revealed that propolis has pharmacological properties.^{18–21} In Southwestern Algeria, propolis used by beekeepers and little is known about its biological activities. A study of Boufadi et al. (2014) reported that propolis harvested from different areas of Algeria contained various high concentrations of polyphenolic compounds known as the main active molecules exhibited free radical scavenging activity.²² The toxicity of Cd increased oxidative stress

and affected urogenital tissues.^{23,24} The decrease in body weight and an increase in prostate gland weight, blood-PSA and Cd²⁺ suggest the Cd-toxicity. This study also showed marked histopathology changes in the prostate tissue. Prostate and testis are the target tissues and are highly sensitive to Cd.^{25,26} Cd, at high dose, induces prostate epithelial cell damage associated with the irregular acini forms. Cd triggers a necrosis of stroma associated with the solid parenchyma areas. The results of this study are compared to other studies performed on the testis in which Cd causes degeneration in spermatogenic cells and the disruption of the connection

complex between Sertoli cells.^{27,28} Other negative effects as high blood testosterone, an increase in blood PSA levels and prostate lesions, were recorded in rats exposed to Cd.^{27,28} Studies of toxicology suggested that Cd is a risk factor associated with prostate cancer.^{20,28,29} The cellular mechanism of Cd toxicity was already elucidated. After Cd absorption, Cd is transported by albumin and hemoglobin to reach the liver. In the liver cells, Cd conjugates to glutathione (GSH) and metallothioneins (MT). The metalloprotein complexes Cd-GSH are excreted in the bile and Cd-MT are stored in the liver or conveyed to the kidney. The Cd-MT complex, in the proximal tubules, leads to 50% excretion of Cd-MT and 50% endocytosis reabsorption. The Cd-MT is transformed by lysosomes thus releasing Cd, which interacts with cellular components, and damage them. High Cd-dose exposure may induce prostate cancer and increase blood PSA.²⁰ Propolis becomes the subject of increasing scientific interest due to its diverse biological properties. It has been shown that propolis have antibacterial, antiviral, and antitumoral activities.^{21,30} This study revealed the protective effect of propolis against Cd-toxicity. Propolis, from different geographic areas and source plants, displays different chemical profiles. Main constituents of European propolis are flavonoid and phenolic acids whereas Mediterranean propolis contains diterpenic acids. This study indicates that propolis treatment showed lower blood PSA and Ca²⁺ levels, a decrease in prostate weight-body weight ratio and less marked prostate necrosis. Caffeic acid phenethyl ester (CAPE), a main active component extracted from propolis, is a strong antioxidant.³¹ CAPE is a specific inhibitor of NF- κ B.³¹ Recent studies suggested that CAPE treatment suppressed the proliferation of used metastatic prostate cancer cell lines such as LNCaP and PC-3 cells. Propolis treatment enhances apoptosis in prostate cancer cells.³² Propolis reduces the angiogenesis process.³³ This occurs by modulating the expression of growth factors such as VEGF and TNF.³⁴ Studies, carried out on the antitumor activity of propolis,³⁵ showed an antiproliferative effect against tumor lines (blood, colon, breast, prostate, lung, liver, brain, kidney).³⁶ Various studies showed that propolis alcohol extract was able to modulate the expression and activity of factors involved in the carcinogenesis process. The antiproliferative effect results from a restoration of the apoptosis signal.³⁷ Cell molecular mechanism of propolis remains unclear. Moreover, more studies are needed to investigate the correlation between propolis intake and prostate cancer incidence.

5. CONCLUSIONS

This study showed that propolis has preventive role against the Cd-toxicity. Propolis reduced accumulation of Cd in the prostate gland and prevents the increase of blood PSA. Though the molecular mechanism of the action of the propolis is unclear, propolis contributes widely to involve the scavenging of free radicals, increasing antioxidant status and metal-chelating abilities.

Conflict of interest

There is no conflict of interest for all authors.

Sources of funding

No funding was received for the work described in this article.

Acknowledgement

The authors wish to thank Dr Z. Haddi for helping biochemical analysis and for his assistance in histological techniques.

References

- Zeng X, Jin T, Jiang X, Kong Q, Ye T, Nordberg GF. Effects on the prostate of environmental cadmium exposure – a cross-sectional population study in China. *Biometals*. 2004;17(5):559–565. <https://doi.org/10.1023/B:BIOM.0000045739.89653.67>.
- Amamou F, Nemmiche S, Meziane RK, Didi A, Yazit SM, Chabane-Sari D. Protective effect of olive oil and colocynth oil against cadmium-induced oxidative stress in the liver of Wistar rats. *Food Chem Toxicol*. 2015;78:177–184. <https://doi.org/10.1016/j.fct.2015.01.001>.
- Chena F, Gong P. Caffeic Acid Phenethyl Ester Protect Mice Hepatic Damage Against Cadmium Exposure. *Procedia Environmental Sciences*. 2011;8:633–636. <https://doi.org/10.1016/j.proenv.2011.10.098>.
- Jung HY, Seo DW, Hong CO, Kim JY, Yang SY, Lee KW. Nephroprotection of plantamajoside in rats treated with cadmium. *Environ Toxicol Pharmacol*. 2015;39(1):125–136. <https://doi.org/10.1016/j.etap.2014.11.012>.
- Liu CC, Hsu JM, Kuo LK, Chuu CP. Caffeic acid phenethyl ester as an adjuvant therapy for advanced prostate cancer. *Med Hypotheses*. 2013;80(5):617–619. <https://doi.org/10.1016/j.mehy.2013.02.003>.
- Ibrahim T, Flamini E, Mercatali L, Sacanna E, Serra P, Amadori D. Pathogenesis of osteoblastic bone metastases from prostate cancer. *Cancer*. 2010;116(6):1406–1418. <https://doi.org/10.1002/cncr.24896>.
- Chuu CP, Kokontis JM, Hiipakka RA, Fukuchi J, Lin HP, Lin CY, et al. Androgens as therapy for androgen receptor-positive castration-resistant prostate cancer. *J Biomed Sci*. 2011;18:63. <https://doi.org/10.1186/1423-0127-18-63>.
- Pinto AC, Moreira JN, Simões S. Liposomal imatinib-mitoxantrone combination: formulation development and therapeutic evaluation in an animal model of prostate cancer. *Prostate*. 2011;71(1):81–90. <https://doi.org/10.1002/pros.21224>.
- Toreti VC, Sato HH, Pastore GM, Park YK. Recent progress of propolis for its biological and chemical compositions and its botanical origin. *Evid Based Complement Alternat Med*. 2013;2013:697390. <https://doi.org/10.1155/2013/697390>.
- Graikou K, Popova M, Gortzi O, Bankova V, Chinou I. Characterization and biological evaluation of selected Mediterranean propolis samples. Is it a new type? *LWT – Food Sci Technol*. 2016;65:261–267. <https://doi.org/10.1016/j.lwt.2015.08.025>.
- Sawicka D, Car H, Borawska MH, Nikliński J. The anticancer activity of propolis. *Folia Histochem Cytobiol*. 2012;50(1):25–37. <https://doi.org/10.5603/FHC.2012.0004>.

- ¹² Salatino A, Fernandes-Silva CC, Righi AA, Salatino ML. Propolis research and the chemistry of plant products. *Nat Prod Rep*. 2011;28(5):925–936. <https://doi.org/10.1039/c0np00072h>.
- ¹³ Kardar MN, Zhang T, Coxon GD, Watson DG, Fearnley J, Seidel V. Characterisation of triterpenes and new phenolic lipids in Cameroonian propolis. *Phytochemistry*. 2014;106:156–163. <https://doi.org/10.1016/j.phytochem.2014.07.016>.
- ¹⁴ Ahn MR, Kumazawa S, Usui Y, et al. Antioxidant activity and constituents of propolis collected in various areas of China. *Food Chemistry*. 2007;101:1383–1392. <https://doi.org/10.1016/j.foodchem.2006.03.045>.
- ¹⁵ Popova MP, Graikou K, Chinou I, Bankova VS. GC-MS profiling of diterpene compounds in Mediterranean propolis from Greece. *J Agric Food Chem*. 2010;58(5):3167–3176. <https://doi.org/10.1021/jf903841k>.
- ¹⁶ Toxicological Data, National Institute of Health (NIH), USA, Technical Database Services (TDS), New York; 2009.
- ¹⁷ Rizk SM, Zaki HF, Mina MAM. Propolis attenuates doxorubicin-induced testicular toxicity in rats. *Food Chem Toxicol*. 2014;67:176–186. <https://doi.org/10.1016/j.fct.2014.02.031>.
- ¹⁸ Scazzocchio F, D'Auria FD, Alessandrini D, Pantanella F. Multifactorial aspects of antimicrobial activity of propolis. *Microbiol Res*. 2006;161(4):327–333. <https://doi.org/10.1016/j.micres.2005.12.003>.
- ¹⁹ Amoros M, Simões CM, Girre L, Sauvager F, Cormier M. Synergistic effect of flavones and flavonols against herpes simplex virus type 1 in cell culture. Comparison with the antiviral activity of propolis. *J Nat Prod*. 1992;55(12):1732–1740. <https://doi.org/10.1021/np50090a003>.
- ²⁰ Silici S, Koç NA, Ayangil D, Cankaya S. Antifungal activities of propolis collected by different races of honeybees against yeasts isolated from patients with superficial mycoses. *J Pharmacol Sci*. 2005;99(1):39–44. <https://doi.org/10.1254/jphs.FPE05002X>.
- ²¹ Feres M, Figueiredo LC, Barreto IM, Coelho MH, Araujo MW, Cortelli SC. In vitro antimicrobial activity of plant extracts and propolis in saliva samples of healthy and periodontally-involved subjects. *J Int Acad Periodontol*. 2005;7(3):90–96.
- ²² Boufadi YM, Soubhye J, Riazi A, et al. Characterization and antioxidant properties of six Algerian propolis extracts: ethyl acetate extracts inhibit myeloperoxidase activity. *Int J Mol Sci*. 2014;15(2):2327–2345. <https://doi.org/10.3390/ijms15022327>.
- ²³ Rajendar B, Bharavi K, Rao GS, Kishore PV, Kumar PR, Kumar CS. Protective effect of alpha-tocopherol on biochemical and histological alterations induced by cadmium in rat testes. *Indian J Physiol Pharmacol*. 2011;55(33):213–220.
- ²⁴ Bashandy SA, Omara EA, Ebaid H, Amin MM, Soliman MS. Role of zinc as an antioxidant and anti-inflammatory to relieve cadmium oxidative stress induced testicular damage in rats. *Asian Pac J Trop Biomed*. 2016;6(12): 1056–1064. <https://doi.org/10.1016/j.apjtb.2016.08.016>.
- ²⁵ EL-Shahat AE, Gabr A, Meki AR, Mehana ES. Altered testicular morphology and oxidative stress induced by cadmium in experimental rats and protective effect of simultaneous green tea extract. *Int J Morphol*. 2009;27(3): 757–764. <https://doi.org/10.4067/S0717-95022009000300020>.
- ²⁶ Adamkovicova M, Toman R, Cabaj M, Massanyi P, Martiniakova M, Omelka R, et al. Effects of subchronic exposure to cadmium and diazinon on testis and epididymis in rats. *The Scientific World Journal*. 2014;2014:632581. <https://doi.org/10.1155/2014/632581>.
- ²⁷ Erboga M, Kanter M, Aktas MC, Bozdemir Donmez Y, Fidanol Erboga Z, Aktas E, et al. Anti-Apoptotic and Anti-Oxidant Effects of Caffeic Acid Phenethyl Ester on Cadmium-Induced Testicular Toxicity in Rats. *Biol Trace Elem Res*. 2011;171(1):176–184. <https://doi.org/10.1007/s12011-015-0509-y>.
- ²⁸ Satarug S, Moore MR. Adverse health effects of chronic exposure to low level cadmium in foodstuffs and cigarette smoke. *Environ Health Perspect*. 2004;112(10):1099–1103. <https://doi.org/10.1289/ehp.6751>.
- ²⁹ Thompson IM, Pauler DK, Goodman PJ, Tangen CM, Lucia MS, Parnes HL, et al. Prevalence of prostate cancer among men with a prostate-specific antigen level < or = 4.0 ng per milliliter. *N Engl J Med*. 2004;350(22):2239–2246. <https://doi.org/10.1056/NEJMoa031918>.
- ³⁰ Wu CC, Pu YS, Wu HC, Yang CY, Chen YC. Reversed association between levels of prostate specific antigen and levels of blood cadmium and urinary cadmium. *Chemosphere*. 2011;83(8):1188–1191. <https://doi.org/10.1016/j.chemosphere.2010.12.085>.
- ³¹ Natarajan K, Singh S, Burke Jr TR, Aggarwal BB. Caffeic acid phenethyl ester is a potent and specific inhibitor of activation of nuclear transcription factor NF-kappa B. *Proc Natl Acad Sci USA*. 1996;93(17):9090–9095. <https://doi.org/10.1073/pnas.93.17.9090>.
- ³² Szliszka E, Czuba ZP, Bronikowska J, Mertas A, Paradysz A, Krol W. Ethanolic Extract of Propolis Augments TRAIL-Induced Apoptotic Death in Prostate Cancer Cells. *Evid Based Complement Altern Med*. 2011;2011:535172. <https://doi.org/10.1093/ecam/nep180>.
- ³³ Keshavarz M, Mostafaie A, Mansouri K, Shakiba Y, Motlagh HR. Inhibition of corneal neovascularization with propolis extract. *Arch Med Res*. 2009;40(1):59–61. <https://doi.org/10.1016/j.arcmed.2008.10.004>.
- ³⁴ Izuta H, Shimazawa M, Tsuruma K, Araki Y, Satoshi M, Hara H. Bee products prevent VEGF-induced angiogenesis in human umbilical vein endothelial cells. *BMC Complement Altern Med*. 2009;9:45. <https://doi.org/10.1186/1472-6882-9-45>.
- ³⁵ Orsolich N. A review of propolis antitumour action in vivo and in vitro. *J AAS*. 2010;2:1–20. <https://doi.org/10.3896/IBRA.4.02.1.01>.
- ³⁶ Valente MJ, Baltazar AF, Henrique R, Estevinho L, Carvalho M. Biological activities of Portuguese propolis: protection against free radical-induced erythrocyte damage and inhibition of human renal cancer cell growth in vitro. *Food Chem Toxicol*. 2011;49(1):86–92. <https://doi.org/10.1016/j.fct.2010.10.001>.
- ³⁷ Avcı CB, Gündüz C, Baran Y, Sahin F, Yılmaz S, Dogan ZO, et al. Caffeic acid phenethyl ester triggers apoptosis through induction of loss of mitochondrial membrane potential in CCRF-CEM cells. *J Cancer Res Clin Oncol*. 2011;137(1):41–47. <https://doi.org/10.1007/s00432-010-0857-0>.