



## Case report

# MRI in diagnostic of diffuse axonal injury

**Urszula Kościuczuk<sup>1</sup>, Andrzej Siemiątkowski<sup>1</sup>, Adam Łukasiewicz<sup>2</sup>**

<sup>1</sup> Department of Anaesthesiology and Intensive Care, Medical University of Białystok, Poland

<sup>2</sup> Department of Radiology, Medical University of Białystok, Poland

### ARTICLE INFO

#### Article history

Received 1 June 2017

Accepted 16 August 2017

Available online 29 June 2018

#### Keywords

Traumatic brain injury

Neurological outcomes

Prognostication

#### Doi

10.29089/2017.17.00057

#### User license

This work is licensed under a Creative Commons Attribution – NonCommercial – NoDerivatives 4.0 International License.



### ABSTRACT

**Introduction:** Diffuse axonal injury (DAI), is a rarely occurring consequence of traumatic brain injury (TBI). For many years identification and outcomes prediction of DAI was limited. The specific markers have not been described. Progress in the development of radiological methods has made current abilities for recognition and prognosis much greater.

**Aim:** The aim of the paper is the presentation of the clinical image of DAI and the emphasis of the importance of magnetic resonance imaging (MRI) in the diagnosis of this neurological condition.

**Case study:** A 66-year-old female was admitted to the Intensive Care Unit (ICU) in the 2nd day after TBI due to cardiovascular and respiratory failure. A suspicion of DAI was formulated on the basis of the brain computed tomography (CT).

**Results and discussion:** The neurological state Glasgow coma scale (GCS) 7 did not correlate with changes observed in CT. The brain MRI presented lesions in the splenium and in the lobe of the corpus callosum, additionally. The intensity of changes in radiological classification of DAI based on brain MRI confirms the neurological state and allows the prognosis formulation.

**Conclusions:** The brain MRI has become important in the diagnosis and prognostication of DAI.

## 1. INTRODUCTION

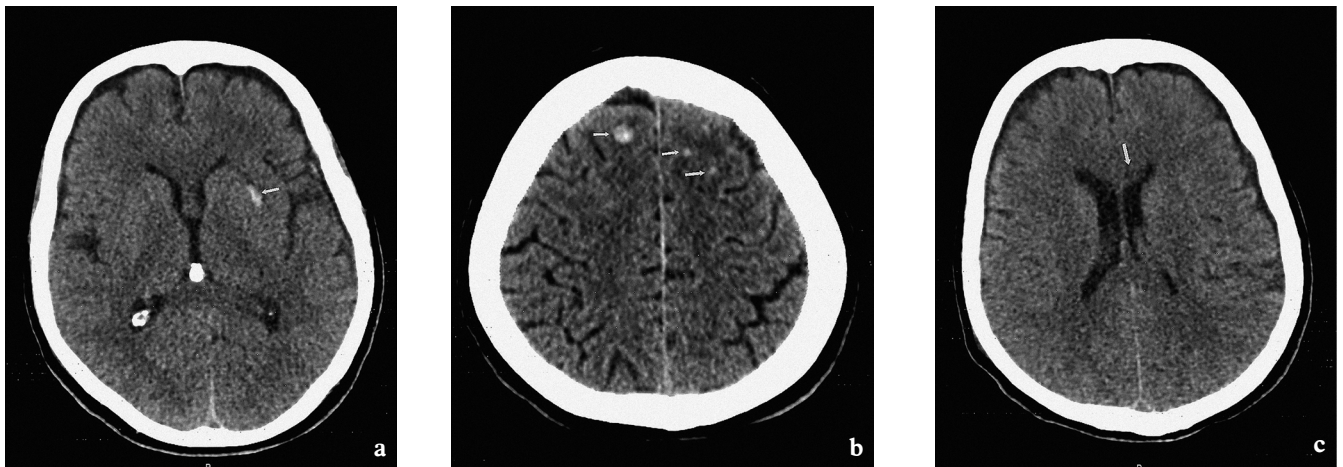
Diffuse Axonal Injury (DAI), initially described by Strich in 1956, is a rarely occurring consequence of traumatic brain injury (TBI).<sup>1</sup> The analysis of TBI in Poland between 2009 and 2012 performed by Miekisiak et al. demonstrated a general frequency 126/105 per year of which DAI constituted 2.11%.<sup>2</sup> The epidemiological data presented above is comparable with trends occurring in many European countries.<sup>3</sup>

For many years diagnosis and identification of DAI was limited. The specific biochemical markers still have not been described.<sup>4–7</sup> Progress in the development of radiological diagnostic methods has made current abilities for recognition and prognosis much greater. Brain computed tomography (CT) is the first choice radiological method to describe consequences of injury, but does not correspond well to the Glasgow coma scale (GCS) score and neurological state. The brain MRI has become especially important in the imaging and confirming diagnosis of DAI.<sup>8–12</sup>

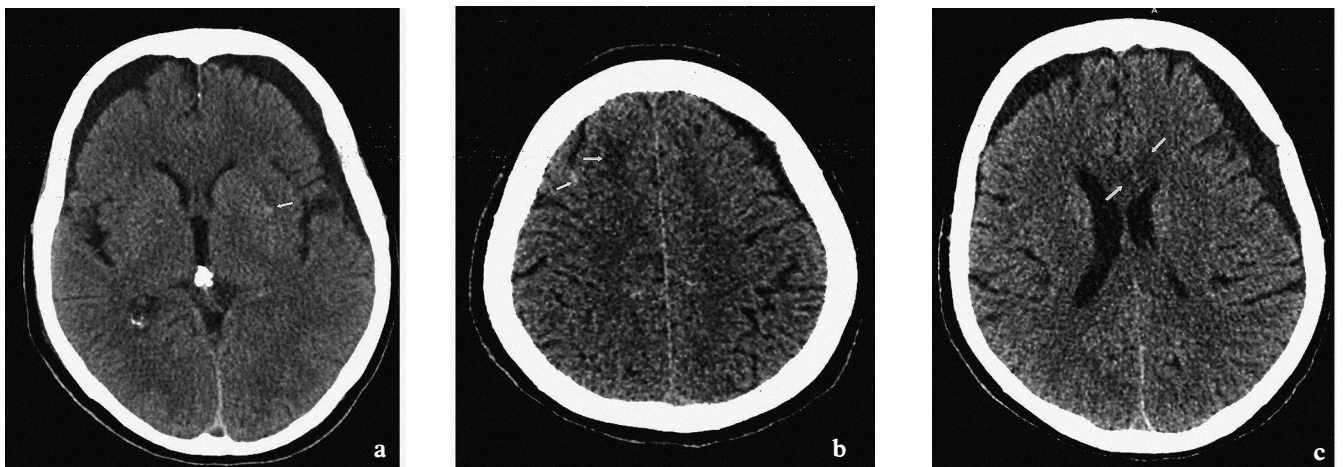
Numerous classifications have been formed to describe severity of DAI and predict outcomes of brain injury.<sup>13–14</sup> Diagnosis of DAI is based on clinical signs and radiological imaging. The treatment of DAI is multidirectional but still not specific.<sup>15–17</sup> The most important management are the cardiac and respiratory stabilization and the prevention of secondary complications connected to the brain injury. Many studies presented positive effects of systemic electrolytes and metabolic stabilization, neuroprotective pharmacotherapy, rehabilitation and local stimulation of healing and regenerative processes.<sup>18–19</sup>

## 2. AIM

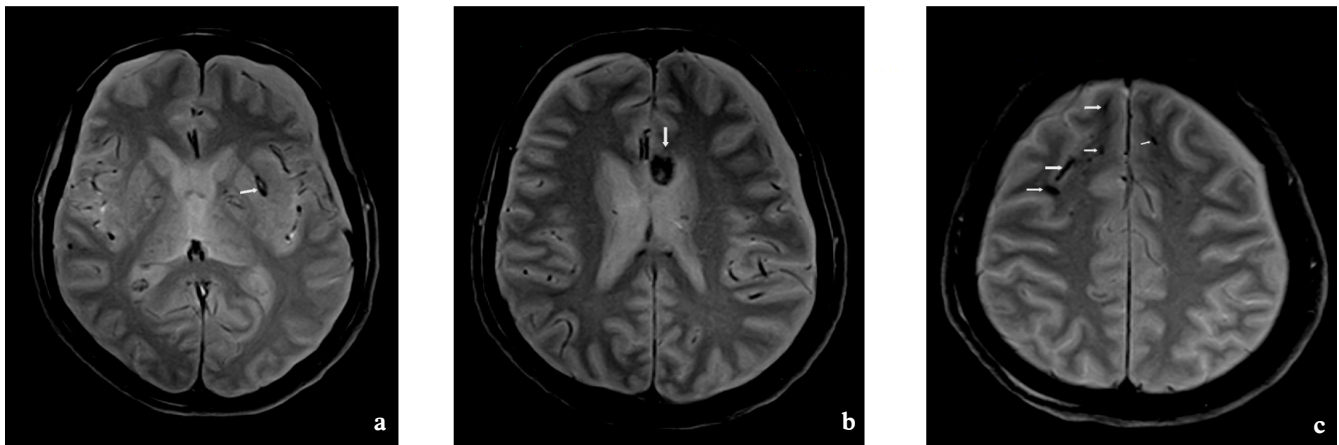
The aim of this paper is the presentation of the clinical image of DAI and the emphasis of the diagnostic importance of MRI in the diagnosis of this neurological condition.



**Figure 1.** Axial CT, day of injury (DOI). Small hemorrhagic focus in left subinsular region – arrow (a) and at the level of the centrum semiovale in the left and right frontal subcortical white matter – arrows (b). Hypodense lesion in genu of corpus callosum is not well seen in CT – arrow (c).



**Figure 2.** Axial CT, 18 days after DOI at the same level like in Figure 1. Partially resorbed hemorrhagic foci, hyper- and hypodense – arrows (a, b). Hypodense lesion in genu of corpus callosum is more evident than on the DOI (c).



**Figure 3.** Axial MRI T2\* images, 20 days after DOI. Better detection of multiple hemorrhagic shearing foci consistent with DAI, seen as hypointense lesions (blood products/hemosiderin) in left subinsular region (a), in anterior part of corpus callosum (b) and in the frontal lobes (c) – arrows.

### 3. CASE STUDY

A 66-year-old female was admitted to the Intensive Care Unit (ICU) from Emergency Department in the 2nd day after TBI resulting from traffic accident due to cardiovascular and respiratory failure. Neurological condition at admittance to the emergency room was following: GCS score 3 (eyes – 1, verbal – 1, motor – 1), pupils even, narrow, non-reactive to light. Additional injuries included numerous right side rib fractures, bruising of the right lung and pneumothorax. The brain CT showed spotted subcortical hemorrhages within the left insular cortex as well as several bleeds in both parietal lobes, no hemorrhagic cortical contusions, a symmetrical ventricular system which was not expanded, with internal structures not displaced, and with the bones of the skullcap without visible posttraumatic changes (Figure 1a–c). A suspicion of DAI was formulated on the basis of the image. Neurosurgical consultation did not qualify the patient for surgical treatment. At admission to ICU the patient was in critical general condition, blocked pharmacologically, intubated and mechanically ventilated, with active intrathoracic drainage, circulation system required stabilization using the infusion of vasopressors. Incomplete, due to the sedation, initial neurological assessment was following: narrow, symmetrical pupils, sluggish reaction to light, tendon reflexes symmetrically preserved, without pathological reflexes.

Subsequent CT scan on day 2 showed no new haemorrhagic lesions. A follow-up brain CT performed on day 7 and day 18 showed smaller subcortical bleeds in the left insular cortex and in both parietal lobes, with the symmetrical ventricular system, not expanded and internal structures not displaced (Figure 2a–c). After complete withholding of sedation a comprehensive neurological assessment was performed. The patient opened eyes in reaction to painful stimulation (2), did not present verbal response (1), withdrawal motor reaction (4) indicating GCS score 7, with slight anisocoria of the pupils L > R, tone muscle and strength was reduced bilaterally, superficial reflexes – positive, symmetrical, without pathological reflexes. Recommendations

for further treatment included neuroprotective therapy and more extensive radiological diagnosis using MRI.

Following MRI scan on day 20 presented multiple areas of signal loss at the gray-white matter junction in both frontal lobes consistent with old microbleeds. Similar foci were seen in the area of the splenium and lobe of the corpus callosum and hemorrhaging lesion within the left subinsular region in the area of the nucleus lentiformis (Figure 3a–c).

Hospitalization at the ICU lasted 71 days. Because of neurological condition tracheostomy was performed. Starting with day 31 the patient was breathing spontaneously with tracheotomy tube and the passive oxygen therapy. The circulatory system was stable and did not require pharmacological support. During hospitalization the neurological condition remained stable. Neurologically no improvement in the consciousness was achieved and remained at GCS score – 7 with Glasgow outcome scale extended (GOSE) – at 3 (lower severe disability).

The prognosis remains limited without possibility for independent functioning. The patient was transferred to the Department of Neurology with a plan for continuation of therapy at Rehabilitation and Care Center.

### 4. RESULTS AND DISCUSSION

DAI is a rare condition resulting from brain injury. The neurological state often cannot be explained by images obtained using CT. Many publications stress the great importance of using MRI to diagnose DAI. In the case study presented above the neurological condition did not correspond to the injuries visible in CT images. Only in the brain MRI characteristic lesions to DAI in the structures of the corpus callosum according to the Marshall classification as a stage II and Rotterdam Classification – 1, became visible.<sup>10–13</sup> The hemorrhaging area localized in corpus callosum were connected with the poor level of consciousness – GCS score – 7.

Observations of patients with DAI conducted by Park et al. indicated that after 10 months medical treatment 52% of



patients recovered a good level of consciousness, 28% were relatively stable, 12% remained in critical condition while 8% slipped into a vegetative state. Patients with grade II injuries had an average GCS score of 7.6 and the mean interval to return consciousness was 12.5 days. Authors showed that 50% of patients with changes caused by hemorrhage in corpus callosum as well as in the brainstem never regained consciousness. The our case study was consistent with the observations of Park et al. illustrating serious and persistent neurological state caused by DAI with changes occurring in the corpus callosum.<sup>20</sup>

The neurological condition remained stable, however, due to lack of improvement of consciousness significantly reduced the possibility for a positive prognosis.

## 5. CONCLUSIONS

The brain MRI is an important element in diagnosis of neurological state in patient with DAI. The discovery of the characteristic changes caused by hemorrhage within brain structures explains neurological deficiencies. The staging in radiological classification reflects the neurological state and allows the formulation of a prognosis.

## References

- 1 Hayes JP, Bigler ED, Verfaellie M. Traumatic brain injury as a disorder of brain connectivity. *J Int Neuropsychol Soc.* 2016;22(2):120–137. <https://doi.org/10.1017/S1355617715000740>.
- 2 Miekisiak G, Czyz M, Tykocki T, Kaczmarczyk J, Zaluski R, Latka D. Traumatic brain injury in Poland from 2009–2012: A national study on incidence. *Brain Inj.* 2016;30(1):79–82. <https://doi.org/10.3109/02699052.2015.1104550>.
- 3 Peeters W, van den Brande R, Polinder S, et al. Epidemiology of traumatic brain injury in Europe. *Acta Neurochir.* 2015; 157(10):1683–1696. <https://doi.org/10.1007/s00701-015-2512-7>.
- 4 Lin Y, Wen L. Inflammatory response following diffuse axonal injury. *Int J Med Sci.* 2013;10(5):515–521. <https://doi.org/10.7150/ijms.5423>.
- 5 Siedler DG, Chuah MI, Kirkcaldie MTK, Vickers JC, King AE. Diffuse axonal injury in brain trauma: insights from alterations in neurofilaments. *Front Cell Neurosci.* 2014;8:1–10. <https://doi.org/10.3389/fncel.2014.00429>.
- 6 Johnson VE, Stewart W, Smith DH. Axonal pathology in traumatic brain injury. *Exp Neurol.* 2013;246:35–43. <https://doi.org/10.1016/j.expneurol.2012.01.013>.
- 7 Li XY, Feng DF. Diffuse axonal injury: novel insights into detection and treatment. *J Clin Neurosci.* 2009;16(5):614–619. <https://doi.org/10.1016/j.jocn.2008.08.005>.
- 8 Maas AIR, Hukkelhoven C, Marshall LF, Steyerberg EW. Prediction of outcome in traumatic brain injury with computer tomographic characteristics: a comparison between the computed tomography classification and combinations of computed tomographic predictors. *Neurosurgery.* 2005;57(6):1173–1182. <https://doi.org/10.1227/01.NEU.0000186013.63046.6B>.
- 9 Kim HJ, Park IS, Kim JH, et al. Clinical analysis of the prognosis of the patients with cerebral diffuse axonal injuries based on gradient – echo MR imaging. *J Korean Neurosurg Soc.* 2001;30(2):168–172. <https://doi.org/10.3340/jkns.2014.56.2.168>.
- 10 Weiss N, Galanaud D, Carpentier A. A combined clinical and MRI approach for outcome assessment of traumatic head injured comatose patients. *J Neurol.* 2008;255(2):217–223. <https://doi.org/10.1007/s00415-008-0658-4>.
- 11 Skandsen T, Kvistad KA, Solheim O. Prognostic value of magnetic resonance imaging in moderate and severe head injury: A prospective study of early MRI findings and one-year outcome. *J Neurotrauma.* 2011;28(5):691–699. <https://doi.org/10.1089/neu.2010.1590>.
- 12 Adams JH, Doyle D, Ford I, Gennarelli TA, Graham DI, McLellan DR. Diffuse axonal injury in head injury: definition, diagnosis and grading. *Histopathology.* 1989;15(1):49–59. <https://doi.org/10.1111/j.1365-2559.1989.tb03040.x>.
- 13 Munakomi S. A comparative study between Marshall and Rotterdam computed tomography – CT scores in predicting early deaths in patients with traumatic brain injury in a major tertiary care hospital in Nepal. *Chin J Traumatol.* 2016;19(1):25–27. <https://doi.org/10.1016/j.cjtee.2015.12.005>.
- 14 Talari H, Fakharian E, Mousavi N, Abedzadeh-Kalahroudi M, Akbari H, Zoghi S. The Rotterdam scoring system can be used as an independent factor for predicting traumatic brain injury outcomes. *World Neurosurg.* 2016;87:195–199. <https://doi.org/10.1016/j.wneu.2015.11.055>.
- 15 Edlow BL, Giacino JT, Hirschberg RE. Unexpected recovery of function after severe traumatic brain injury. The limits of early neuroimaging-based outcome prediction. *Neurocrit Care.* 2013;19(3):364–375. <https://doi.org/10.1007/s12028-013-9870-x>.
- 16 Carter EL, Hutchinson PJA, Koliass AG, et al. Predicting the outcome for individual patients with traumatic brain injury: a case-based review. *Br J Neurosurg.* 2016;30(2):227–232. <https://doi.org/10.3109/02688697.2016.1139048>.
- 17 Smith DH, Hicks R, Povlishock JT. Therapy development for diffuse axonal injury. *J Neurotrauma.* 2013;30(5):307–323. <https://doi.org/10.1089/neu.2012.2825>.
- 18 Li J, Li XY, Feng DF, Pan DC. Biomarkers associated with diffuse traumatic axonal injury: exploring pathogenesis, early diagnosis and prognosis. *J Trauma.* 2010;69(6):1610–1618. <https://doi.org/10.1097/TA.0b013e3181f5a9ed>.
- 19 Povlishock JT, Katz DI. Update of neuropathology and neurological recovery after traumatic brain injury. *J Head Trauma Rehabil.* 2005;20(1):76–94. <https://doi.org/10.1097/00001199-200501000-00008>.
- 20 Park SJ, Hur JW, Kwon YK, et al. Time to recover consciousness in patients with diffuse axonal injury: assessment with reference to magnetic resonance grading. *J Korean Neurosurg Soc.* 2009;46:205–209. <https://doi.org/10.3340/jkns.2009.46.3.205>.