

Available online at [www.sciencedirect.com](http://www.sciencedirect.com)

ScienceDirect

journal homepage: <http://www.elsevier.com/locate/poamed>

## Case report

# Successful treatment of pulmonary alveolar proteinosis with whole lung lavage and subcutaneous GM-CSF



Virginija Šileikienė<sup>a,b,\*</sup>, Vyantas Gruslys<sup>a,b</sup>, Ingrida Zeleckienė<sup>c</sup>,  
Rolandas Zablockis<sup>a,b</sup>, Robertas Samalavičius<sup>d</sup>, Edvardas Danila<sup>a,b</sup>

<sup>a</sup> Clinic of Infectious and Chest Diseases, Dermatovenereology and Allergology, Vilnius University, Faculty of Medicine, Vilnius, Lithuania

<sup>b</sup> Center of Pulmonology and Allergology, Vilnius University Hospital Santariskiu Klinikos, Vilnius, Lithuania

<sup>c</sup> Center of Radiology and Nuclear Medicine, Vilnius University Hospital Santariskiu Klinikos, Vilnius, Lithuania

<sup>d</sup> Center of Anesthesiology, Vilnius University, Lithuania

## ARTICLE INFO

## Article history:

Received 1 February 2016

Received in revised form

30 June 2016

Accepted 14 November 2016

Available online 30 November 2016

## Keywords:

Pulmonary alveolar proteinosis

Whole lung lavage

Crazy-paving

Granulocyte macrophage colony-stimulating factor

## ABSTRACT

**Introduction:** Pulmonary alveolar proteinosis (PAP) is a rare lung disease characterized by the accumulation of a periodic acid-Schiff-positive lipoproteinaceous material (surfactant) in the distal airways. The standard treatment is whole lung lavage (WLL), however, not all patients respond well to WLL.

**Aim:** We present an exciting case report on the successful treatment of the rare disease PAP with WLL and subcutaneous granulocyte macrophage colony-stimulating factor (GM-CSF) therapy for 12 weeks.

**Case study:** A 20 year-old woman with a 7-month history of progressive shortness of breath was referred to us. Computed tomography of the chest revealed typical geographic ground-glass opacity combined with interlobular septal thickening (crazy paving). Pulmonary function tests showed restriction with severe impairment of diffusion capacity (DL<sub>CO</sub> 20%). Milky bronchoalveolar lavage fluid (BALF) was detected during bronchoscopy. The cytology of the BALF was consistent with PAP. WLL was performed and subcutaneous GM-CSF was started immediately and continued for 12 weeks. At the end of treatment, the patient's lung function was clearly improved (DL<sub>CO</sub> 62%).

**Results and discussion:** One year after the withdrawal of treatment, the patient remains in good health, with no recurrence of hypoxemia and respiratory symptoms. Different treatment modalities have been applied since PAP was first defined, and WLL has been the preferred first line of treatment. Although our patient's condition improved after WLL, her respiratory insufficiency persisted. Consequently, we initiated treatment with subcutaneous GM-CSF.

\* Correspondence to: Clinic of Infectious and Chest Diseases, Dermatovenereology and Allergology, Vilnius University, Faculty of Medicine, Vilnius, Lithuania. Tel.: +370 61291312; fax: +37068862371.

E-mail address: [virginija.sileikiene@santa.lt](mailto:virginija.sileikiene@santa.lt) (V. Šileikienė).

Conclusions: WLL significantly improved our patient's condition, and GM-CSF was effective at prolonging pulmonary washout from excess surfactant.

© 2016 Warmińsko-Mazurska Izba Lekarska w Olsztynie. Published by Elsevier Sp. z o.o. All rights reserved.

## 1. Introduction

Pulmonary alveolar proteinosis (PAP) is a rare lung disease characterized by the accumulation of a periodic acid-Schiff (PAS)-positive lipoproteinaceous material (surfactant) in the distal airways, resulting in various degrees of impaired gas transfer. The clinical manifestations of PAP range from asymptomatic to severe respiratory failure. Three forms of PAP are recognized: congenital – due to mutations in the surfactant or the granulocyte macrophage colony-stimulating factor (GM-CSF) receptor; secondary – related to myeloid malignancy, bone marrow transplantation, infection, and pneumoconiosis; and acquired or autoimmune – related to anti GM-CSF antibodies.<sup>1</sup> Autoimmune PAP covers approximately 90% of all PAP cases. The prevalence of PAP varies from 4 to 40 cases per 1 million, and the incidence is estimated at nearly 0.2 cases per 1 million.<sup>2</sup> The most common symptoms of PAP are dyspnea and cough. Radiographic imaging typically reveals centrally located bilateral symmetric alveolar opacities in the mid and lower lung zones, and bronchoalveolar lavage fluid (BALF), which typically has a milky appearance. For patients with moderate to severe symptoms, the standard treatment is whole lung lavage (WLL), wherein large quantities of saline are instilled into the lungs to remove the proteinaceous material. However, not all patients respond well to WLL; therefore, numerous therapies that enhance the clearance of the surfactant have been investigated. These therapies either target alveolar macrophages with exogenous GM-CSF or reduce the levels of anti-GM-CSF antibodies with plasmapheresis or rituximab.<sup>3</sup>

## 2. Aim

We present a case report of the successful treatment of alveolar proteinosis by subcutaneous GM-CSF after WLL.

## 3. Case study

A 20-year-old woman with a 7-month history of progressive shortness of breath without clinical signs of infection or obstruction was referred to us. The patient was a nonsmoker with no prior environmental or occupational organic/inorganic dust exposure. The chest radiographs showed bilateral air space consolidation. Computed tomography (CT) of the chest revealed typical geographic ground-glass opacity combined with interlobular septal thickening (crazy paving) (Fig. 1a and b). Pulmonary function tests showed restriction with severe impairment of diffusion capacity ( $DL_{CO}$  20%), and

arterial blood gas analysis confirmed severe hypoxemia ( $pO_2$  44.5 mmHg,  $sO_2$  81.7%,  $pCO_2$  23.9 mmHg). Milky BALF was detected during bronchoscopy. The cytology of the BALF was consistent with PAP (positive PAS staining). Based on these findings, PAP was diagnosed.

Due to the severity of the patient's condition, WLL was performed (left lung on August 6, 2014; right lung on August 12, 2014) (Figs. 2 and 3). Five days after right lung lavage, pulmonary function was slightly improved ( $DL_{CO}$  31%), and a CT image showed decreased ground glass opacity, with the exception of the superior left lobe, where crazy paving

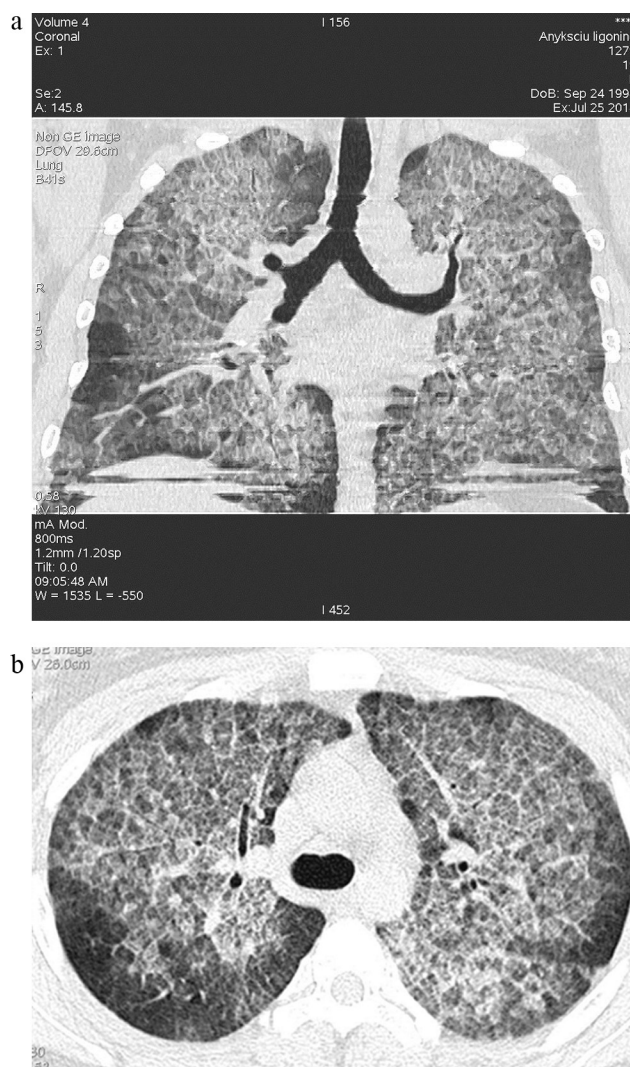
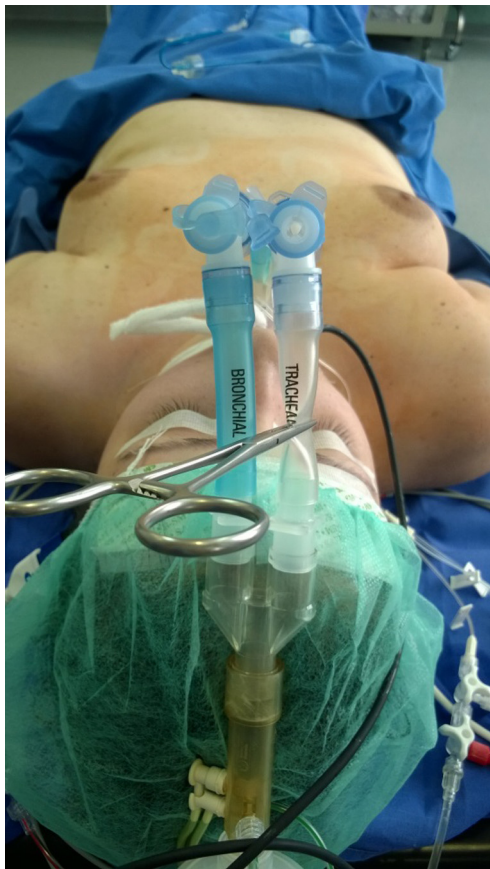

Fig. 1 – (a and b) CT scan (axial and coronal reformatted image, lung window) demonstrating widespread ground-glass opacity, thickened interlobular septa and intralobular lines (crazy-paving pattern).



**Fig. 2 – WLL procedure using double-lumen tubes for lavaging each lung in order to physically remove the accumulated alveolar lipoproteinaceous material.**

remained (Fig. 4a and b). Due to persistent respiratory insufficiency, subcutaneous GM-CSF 300 mcg daily was started immediately and continued for 12 weeks.

At the end of treatment, the patient's clinical and laboratory signs of respiratory insufficiency disappeared, and her lung function was clearly improved ( $DL_{CO}$  – 62%). Decreased ground-glass opacity and crazy-paving was noted on a CT scan, including the upper left lobe, which had remained affected after WLL (Fig. 4c and d).



**Fig. 3 – A total of 12 L of warmed (37 °C) saline were used for WLL. The lungs were washed until the solution appeared clear.**

#### 4. Results and discussion

An year after withdrawal of treatment, the patient is still in good health with no recurrence of hypoxemia and respiratory symptoms ( $DL_{CO}$  is monitored every 3 months and remains stable in the 58%, 51%, 50% range).

PAP is a disease of impaired alveolar macrophage function that leads to an excessive accumulation of surfactant components in the alveoli.

Patients are typically 20–50 years old at presentation<sup>4,5</sup>; our patient was 20 years old.

The symptoms and physical findings of our patient were nonspecific, which is characteristic of most patients with this disease. Chest radiographic imaging revealed symmetric, bilateral alveolar opacities, and CT scans showed ground-glass opacities and crazy-paving, which suggested interstitial lung disease. A crazy-paving pattern is suggestive of, but not specific, to PAP. Crazy-paving can be associated with lesional or cardiogenic pulmonary edema, alveolar hemorrhage, pulmonary infection (mycoplasma, pneumocystis), exogenous lipid pneumonia or bronchioloalveolar carcinoma.<sup>6</sup> The extent of the opacities seen on a CT scan is apparently associated with impaired pulmonary function upon testing.<sup>7</sup> Our patient's lungs on a CT scan were severely damaged, and we detected a severe reduction of her diffusion capacity for  $DL_{CO}$  by pulmonary function testing.

BALF staining is required for the diagnosis of PAP.<sup>8</sup> BALF typically has a milky appearance. Cytological examination and PAS staining are also mandatory for the diagnosis of PAP. In our case, the patient's BALF had a milky appearance. A cytological examination was performed, and PAS staining was found to be positive. Due to the serious nature of our patient's condition, we were not able to perform a trans-bronchial lung biopsy, however, if typical BALF and CT findings are present, a lung biopsy is not necessary for the diagnosis of PAP.<sup>2</sup> Our presented case was considered to have PAP based on clinical symptoms, blood gas analysis, radiologic findings, BALF findings, and the exclusion of other possible conditions.

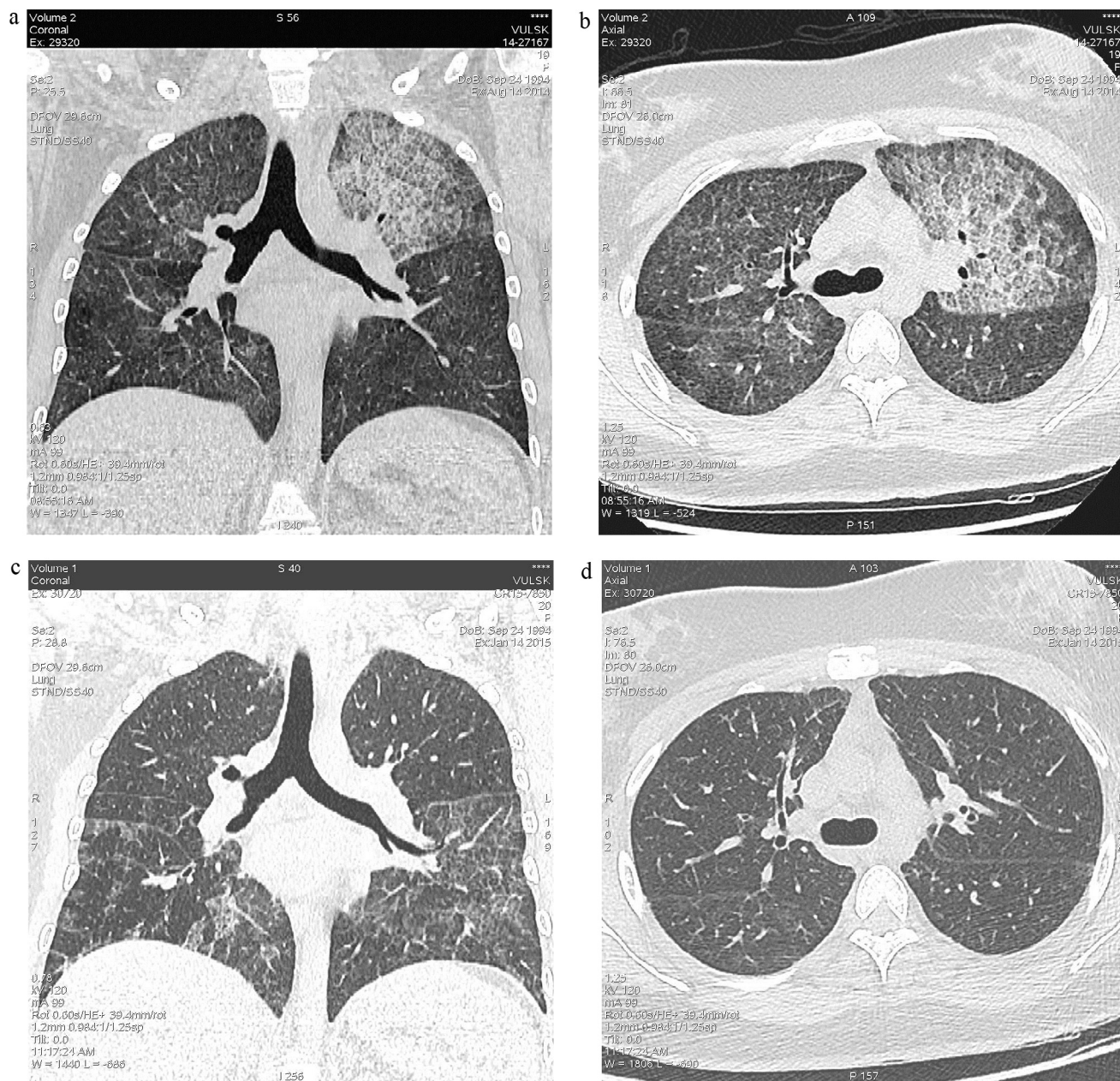
Anti GM-CSF antibodies are found in the majority of PAP patients. Because anti GM-CSF antibodies were unavailable in Lithuania when our study was conducted, we were unable to study these antibodies.

Different treatment modalities have been applied since PAP was first defined, and WLL has been the preferred first line of treatment. The outcome of WLL was studied by Shah et al., who found that 60% of PAP patients recovered after two lavages of each lung, 15% of PAP patients required a new WLL every 6 months, and less than 10% of PAP patients failed to respond to WLL.<sup>9</sup> Our patient had severe progressive respiratory insufficiency, thus, we initiated treatment with bilateral WLL. This procedure was performed successfully without any complications.

Other therapies to treat PAP have targeted alveolar macrophages with GM-CSF substitution or reduced the levels of circulating auto-antibodies with rituximab and experimental plasmapheresis.

Although our patient's condition improved after WLL, her respiratory insufficiency persisted. Consequently, we





**Fig. 4 – (a and b) Post-BAL CT scan (axial and coronal reformatted image, lung window) demonstrates the near-complete resolution of ground-glass opacity in the right lung and the lower lobe of the left lung as well as the residual crazy-paving pattern in the upper lobe of the left lung. After medical treatment, a CT scan (lung window) obtained at the identical level reveals residual septal lines and a nearly-complete resolution of ground-glass opacity, including the upper left lobe (c and d).**

initiated treatment with subcutaneous GM-CSF. Our patient tolerated the treatment well, and the only adverse event was an episodic increase of blood leukocytes (up to a maximum of  $49 \times 10^9$  L).

We were disappointed when we saw that the patient's left upper lobe remained unclear after WLL (Fig. 4a and b). In our opinion, this was likely due to intubation tube displacement. Subsequently, this lobe became an important indicator of GM-CSF treatment efficacy, because after

GM-CSF treatment the patient's left upper lobe was virtually clear (Fig. 4c and d).

## 5. Conclusions

Our case report shows the beneficial effect of treating a patient with PAP with subcutaneous GM-CSF immediately following WLL. WLL significantly improved our patient's condition, and

GM-CSF was effective at prolonging pulmonary washout from excess surfactant.

---

### Conflicts of interest

All of the named authors hereby declare that they have no conflicts of interest to disclose.

No foundation was necessary to conduct this study.

### REFERENCES

---

1. Luisetti M, Kadija Z, Mariani F, Rodi G, Campo I, Trapnell BC. Therapy options in pulmonary alveolar proteinosis. *Thorax*. 2010;4(4):239-248.
2. Borie R, Danel C, Debray MP, et al. Pulmonary alveolar proteinosis. *Eur Respir Rev*. 2011;20(120):98-107.
3. Leth S, Bendstrup E, Vestergaard H, Hilberg O. Autoimmune pulmonary alveolar proteinosis: treatment options in year 2013. *Respirology*. 2013;18(1):82-91.
4. Ioachimescu OC, Kavuru MS. Pulmonary alveolar proteinosis. *Chronic Res Dis*. 2006;3(3):149-159.
5. Seymour JF, Presneill JJ. Pulmonary alveolar proteinosis: progress in the first 44 years. *Am J Respir Crit Care Med*. 2002;166(2):215-235.
6. Johkoh T, Iton H, Muller NL, et al. Crazy-paving appearance at thin-section CT: spectrum of disease and pathologic findings. *Radiology*. 1999;211:155-160.
7. Lee KN, Levin DL, Webb WR, Chen D, Storto ML, Golden JA. Pulmonary alveolar proteinosis: high-resolution CT, chest radiographic, and functional correlations. *Chest*. 1997;111(4):989-995.
8. Wells AU. The clinical utility of bronchoalveolar lavage in diffuse parenchymal lung disease. *Eur Respir Rev*. 2010;19(117):237-241.
9. Shah PL, Hansell D, Lawson PR, Reid KB, Morgan C. Pulmonary alveolar proteinosis: clinical aspects and current concepts on pathogenesis. *Thorax*. 2000;55(1):67-77.