

Available online at [www.sciencedirect.com](http://www.sciencedirect.com)
**SciVerse ScienceDirect**
journal homepage: [www.elsevier.com/locate/poamed](http://www.elsevier.com/locate/poamed)

## Review Article

# Selected palatal suture expansion techniques in the treatment of transverse maxillary narrowings – Literature review



Maciej Dobrzyński<sup>\*,1</sup>, Katarzyna Miśków, Krzysztof Dowgierd

Stomatological Outpatient Clinic in Olsztyn, Poland

### ARTICLE INFO

#### Article history:

Received 1 September 2013

Received in revised form

28 September 2013

Accepted 17 October 2013

Available online 19 October 2013

#### Keywords:

Maxillary narrowing

Distractor

SARPE palatal suture

### ABSTRACT

**Introduction:** Palatal suture expansion techniques are used to treat severe maxillary narrowing and lead to its base extending. The palatal suture expansion procedure was for the first time described by Angell in 1860.

**Aim:** To review the palatal suture expansion methods, particularly surgically-assisted rapid maxillary expansion technique and indications for their choice as well as possible complications. Gum-teeth complications associated with the use of orthodontic-orthopedic devices and lack of their efficacy in adult patients contributed to designs invention directly fixed in the palatal bone.

**Discussion:** Anatomic structure of palatal suture changes with age. Palatal suture ossification status determines the choice of one of the orthodontic-orthopedic methods of treatment, which include slow maxillary expansion (SME) or rapid maxillary expansion (RME), as well as the surgically-assisted rapid expansion of the maxillae (SARME/SARPE). In orthodontic-orthopedic methods of palatal suture expansion Haas and Hyrax devices are applied. In the method of surgically-assisted rapid palatal expansion (SARPE), a distractor is placed in the maxilla after *Le Fort I* osteotomy performance. Screws are a source of force for expanding devices both orthodontic-orthopedic and palatal distractors which can be activated by patients. It should be noted that surgically-assisted rapid maxillary expansion (SARME) is a relatively new method, and despite it giving great opportunities of stable maxillary expansion in adult patients, it also raises some concerns related to the surgical intervention and necessity for general anesthesia.

**Conclusions:** SARME expansion technique has particular advantages which include the possibility of application among adult patients, no relapses, as well as the skeletal but not dentoalveolar expanding of maxilla.

© 2013 Warmińsko-Mazurska Izba Lekarska w Olsztynie. Published by Elsevier Urban & Partner Sp. z o.o. All rights reserved.

\*Correspondence to: Stomatological Outpatient Clinic in Olsztyn, Żołnierska 18, 10-561 Olsztyn, Poland. Tel.: +48 604 795 947.

E-mail address: [maciejdobrzyński@op.pl](mailto:maciejdobrzyński@op.pl) (M. Dobrzyński).

<sup>1</sup>Dentist, during specialization in Orthodontics. Specialization carried out at Specialist Orthodontics Outpatient Clinic, Mickiewicza 33/1, 10-508 Olsztyn, Poland.

## 1. Introduction

Palatal suture expansion techniques are used to treat severe maxillary narrowing and lead to its base extending. Maxillary narrowings are characterized by partial bilateral crossbite and high gothic palate.<sup>1,2,3,6</sup> The result of reducing the transverse dimension of maxilla is limitation of space for the teeth which in consequence leads to crowding. Palatal suture ossification status determines the choice of one of the methods of treatment, which include slow maxillary expansion (SME) or rapid maxillary expansion (RME), as well as the surgically-assisted rapid expansion of the maxilla.<sup>3,6</sup>

Anatomic structure of palatal suture changes with age. In the primary or early mixed dentition, two palatine processes of maxilla bones are joined via connective tissue symphysis containing a large number of collagen fibers and undifferentiated mesenchymal cells. During this period, the palatal suture can be relatively easily expanded by applying forces less than 1 kg.<sup>1,2</sup> In the period of late mixed dentition, as a result of symphysis ossification, palatal suture becomes narrow and takes the sinusoidal shape.<sup>1,5</sup> In this case, palatal suture expansion requires applying stronger forces to separate palatine processes of maxilla. In late adolescence, palatal suture can be completely ossified resembling the shape of zip-fastener. During this period, palatal suture expansion often requires the use of high orthodontic forces of 5–10 kg. In such case, there is also a risk of abutment teeth breakage or alveolar bone fracture.<sup>1,2</sup> The pain may accompany this method of treatment and the effects are less stable as maxillary narrowing recurrence might be present in more than 60% of cases.<sup>2</sup>

## 2. Aim

To review the palatal suture expansion methods, particularly SARME technique and indications for their choice as well as possible complications.

## 3. Discussion

The choice of one of the maxillary expansion methods: orthopedic-orthodontic ones or surgically-assisted method depends on state of palatal ossification and degree of maxillary narrowing.

## 4. Orthopedic-orthodontic palatal suture expansion methods

The palatal suture expansion procedure was for the first time described by Angell in 1860 who was a dentist in San Francisco. It was performed in a 14.5-year-old female patient and resulted in an increase in transverse maxillary dimension approximately for 6 mm as well as the appearance of median diastema.<sup>5,14</sup> However, the criticism of such treatment associated with too high forces transmitted by anchor teeth and hampered oral hygiene contributed to the rare application of the above procedure in the U.S.<sup>5</sup> The

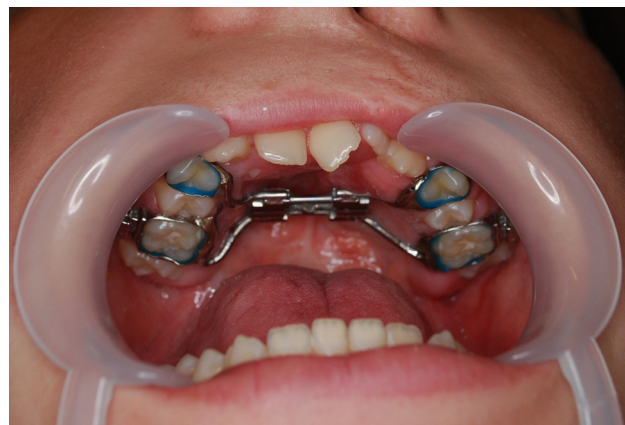renaissance of this method in the U.S. took place in the 1960s as a technique of rapid palatal suture expansion. It consisted in daily screw activation (0.5–1.0 mm) placed in a fixed appliance which was mounted on posterior teeth by cemented orthodontic bands. This activation generates a force of 4.5–9.0 kg across the palatal suture. After 2–3 weeks activation period follows 3–4 weeks of retention period, during which the new bone tissue is formed in the space of expanded mid-palatal suture. Evaluation of such treatment results showed that only in the initial phase of therapy, expansion range of the body of maxilla exceeds degree of expansion of the alveolar process and reaches a dimension of 10 mm. However, during the retention period a partial recurrence of maxillary narrowing is observed and alveolar expansion begins to dominate. In the final result of the therapy, only half of the obtained expansion constitutes of bone expansion and the rest constitutes of tooth expansion.<sup>1,2,9,13</sup>

The disadvantage of rapid palatal suture expansion technique presented above, has been eliminated by the introduction of slow palatal suture expansion method. In this method the screw activation is less frequent (1 mm per week) resulting in generation of forces in range of 0.9–2.0 kg. The longer activation time carried over 10 weeks makes the method less traumatic. It has been shown that a 3-month retention period assures similar to RME method expansion of 10 mm. In this case, bone and teeth component of palatal expansion have equal participation.

In both presented methods of palatal suture expansion Haas and Hyrax devices are applied. In the Haas device the screw is placed between two acrylic plates covering the palate, while in the Hyrax (Fig. 1) device the screw is attached to the two metal supports. Both constructions are fixed to the premolars and molars of maxilla by the orthodontic bands.

Among children where the course of the palatal suture is straight, maxilla expansion can be achieved using devices designed to extend the upper dental arch, which include Quadhelix, Nickel-titanium palatal expander, Schwarz plate.<sup>8,9</sup>

The complications observed during the application of orthodontic-orthopedic palatal expansion methods including teeth extrusions, lateral tilting of the teeth and alveolar



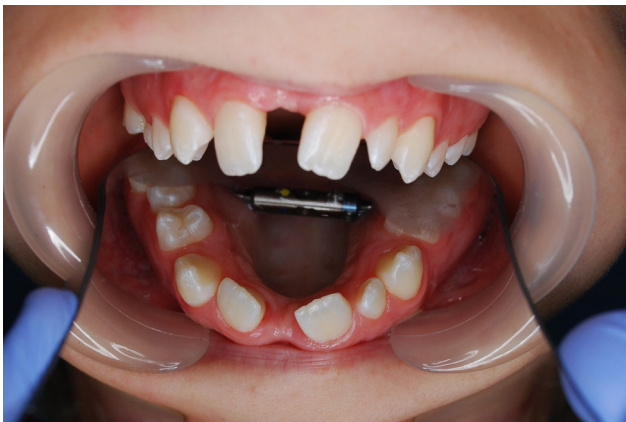**Fig. 1 – Correction of the maxillary narrowing in patient after cleft of primary and secondary palate using Hyrax device. From the collection of Center of Craniofacial Defects Treatment and Maxillofacial Surgery in Olsztyn.**

processes, unwanted bending of the alveolar bone, atrophy vestibular lamina of the alveolar bone, gingival recessions, tissue necrosis of the soft palate, adverse palatal opening, periodontal compression of the buccal surface of dental root, buccal roots resorption, bone atrophy within vestibular lamina and instability of palatal expansion.<sup>3,12</sup> To eliminate the above orthopedic treatment complications, the surgical techniques were introduced.

## 5. Surgically-assisted rapid maxillary expansion methods

In this group of methods, surgically-assisted rapid palatal expansion (SARPE) and maxillary osteotomy procedure (applied during correction of the maxillo-occlusal abnormalities) are distinguished. These procedures are performed under general anesthesia.

Indications for SARPE include cross bites, crowding accompanied by contraindications for teeth extraction, large side corridors in adult patients, patients over 14 years old (although the limit of age is still under discussion), preparation for orthognatic surgery reducing the risk of incorrect alignment of bone fragments and instability of the surgery



**Fig. 2 – Correction of the maxillary narrowing using UNI-Smile distractor. From the collection of Center of Craniofacial Defects Treatment and Maxillofacial Surgery in Olsztyn.**

results, maxillary narrowing in clefts of palate or ineffectiveness of orthodontic-orthopedic methods application.<sup>12</sup>

In the method of SARPE a distractor is placed in the upper jaw after maxilla *Le Fort I* osteotomy performance. Cutline within maxilla extends through its posterior surface, zygomaticoalveolar crest, anterior wall of the maxillary sinus and the medial edge of the piriform aperture. Subsequently in the midline between maxillary central incisors roots the osteotomy is performed. The junction between pterygoid process and maxillary tuberosity is also released. In each case, the nasal septum is cut off from the base of nasal cavity bottom.<sup>3</sup>

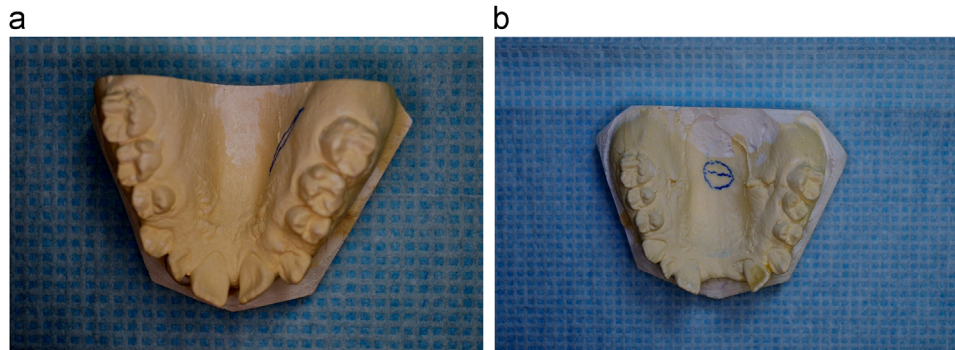
After performing osteotomy, the maxillary palatal mucosa is cut between second premolar and first molar exposing bone and the palatal distractor is placed. One of such designs is the UNI-Smile Distractor device (*Titamed*), constructed with two distraction screws and sleeves. It is based (placed) on the maxillary palatal processes by two platforms fixed within the interradicular spaces with self-drilling screws (*Fig. 2*). The distractor is activated using “bottle screw.”<sup>3</sup> After device placing, the surgeon activates the distractor. This procedure involves appearance of about 1 mm gap between the maxillary central incisors and following blocking screw insertion.

During the treatment using palatal distractor three periods are distinguished: latency, distraction and retention. After a period of 5–7 days, blocking screw is removed and distraction screw is activated twice a day, 0.25 mm/rev, depending on the range of distraction (*Fig. 3*). A period of stabilization lasting 3–6 months is followed by a period of distraction.<sup>3,10</sup>

Possible complications after distraction procedure include: intra-operative complications (bleeding, damage of the root of the tooth), as well as early postoperative complications such as edema, swelling, bleeding. Further complications may occur during distractor activation (distractor unscrewing/taking to pieces, screws loosening or unsymmetrical distraction), as well as after device blocking (screws slackening, pain).

Based on the literature, in the SARPE method the various designs of distractors are applied; however, they have a similar protocol of distraction, the latency period as well as they are accompanied by a similar surgical procedure of the maxillary bones release.

In the studies of palatal distraction carried out by Pinto et al., the transpalatal distractor (*Surgi-Tec NV*) – curtly TPD – was used. TPD was placed at the second premolar level and



**Fig. 3 – (a) Model of maxilla in patient from Fig. 2 (before distraction), reducing the transverse dimension. From the collection of Center of Craniofacial Defects Treatment and Maxillofacial Surgery in Olsztyn. (b) Model of maxilla in patient from Fig. 2, state after distraction. Obtained widening of the anterior width of dental arch (7 mm) and posterior (10 mm) according to Pont. From the collection of Center of Craniofacial Defects Treatment and Maxillofacial Surgery in Olsztyn.**

a surgical procedure did not involve pterygomaxillary separation. The expansion began 7 days after surgery according to protocol 0.33 mm/day. The measurements on digital photographs of orthodontic models obtained from 20 adult patients were performed immediately before and after distraction. Changes in the intercanine (C-C), interpremolar (P-P) and intermolar (M-M) width, in dental arch perimeter were estimated. Width expansions of 35.7% (C-C), 31.7% (P-P), and 22.7% (M-M) were observed, respectively. Furthermore the mean value of the arch perimeter increased by 10.5%. Increase in the transverse dimension at the canine level was 1.5 times greater than at the molar level. According to cited authors, the arch perimeter change can be predicted based on the expansion at the canines and the premolars level.<sup>11</sup>

Gerlach and Zahl performed transversal expansion of the maxillary bones preceded by osteotomy within the side walls of the maxillary sinuses as well as the median palatal suture on 10 patients (mean age 25.8 years) applying palatal distractor. After a 3-week period of distraction, there was an increase in the intercanine width (C-C) by an average of 8.8 mm, an increase in the interpremolar width (P-P) by an average of 8.6 mm and the intermolar width (M-M) by an average of 8.3 mm.<sup>4</sup> After 6 months of fixed appliance treatment the result achieved at the end of distraction was maintained.

Koudstaal et al. used the Rotterdam distractor (the design is similar to scissor car lift) in 13 patients with transverse maxillary hypoplasia, aged 12–34 years old. Before placing the distractor the front-, side- and midline corticotomy of maxilla were performed without separating it from the pterygoid process of sphenoid bone. After a 3-week distraction period authors achieved the transverse maxillary expansion of 6–19 mm.<sup>7</sup>

Dowgierd<sup>3</sup> in his study used a previously described distractor *Titamed* in 20 patients (mean age 16.6). Surgical procedure consisted of a maxillary osteotomy *Le Fort I* and osteotomy in the midline between the roots of the maxillary central incisors. The distractor was activated according to the protocol – twice a day for 0.25 mm. Mean duration of distraction was 18.90 days. The mean increase of the intercanine width (C-C) – 11.97 mm, in the interpremolar width (P-P) – 5.36 mm the intermolar width (M-M) – 6.23 mm were achieved.

The results presented above confirm the possibility of SARPE method application among adult patients, and the time needed to the maxillary bones extension is 3 weeks. However, most of the achieved expansion is in the intercanine segment.

## 6. Conclusions

From the presented two groups of methods of palatal suture expansion, surgically-assisted rapid maxillary expansion

technique has particular advantages which include the possibility of application among adult patients, no relapses, as well as the skeletal but not dentoalveolar expanding of the upper jaw.

## Conflict of interest

None declared.

## REFERENCES

- [1] Biedziak B. Ocena zmian w górnym łuku zębowym po rozsunięciu szwu podniebiennego. *Czas Stomatol.* 2009;62(9):764–772 [in Polish].
- [2] Biedziak B, Kurzawski M. Ortopedyczno-ortodontyczne leczenie zwężenia szczęki metodą rozsunienia szwu podniebiennego. *Nowa Stomatol.* 2004;3:122–124 [in Polish].
- [3] Dowgierd K. Dystrakcja transwersalna szczęki – doniesienie wstępne. [Internet]. [accessed: 1 Sep 2012]. Available at: <http://chirurgiaszczekowa.olsztyn.pl/dokumenty/artykulsarme.pdf> [in Polish].
- [4] Gerlach KL, Zahl C. Transversal palatal expansion using a palatal distractor. *J Orofacial Orthop.* 2003;64(6):443–449.
- [5] Góź G. Szybkie poszerzenie podniebienia (rozsuniecie szwu podniebiennego). [W:] *Ortodoncja II. Leczenie.* Red. A. Dietricha. Wrocław: Urban & Partners; 2004 [in Polish].
- [6] Kamińska I. Efekty ortodontyczne rozsuwania szwu podniebiennego. *Ann Acad Med Stetin.* 2008;54(1):94–105 [in Polish].
- [7] Koudstaal MJ, van der Wal KGH, Wolvius EB, Schulten AJM. The Rotterdam Palatal Distractor: introduction of the new bone-borne device and report of the pilot study. *Int J Oral Maxillofac Surg.* 2006;35:31–35.
- [8] Kurzawski M, Biedziak B. Budowa i działanie niklowo-tytanowego ekspandera (NPE – 2<sup>®</sup>). *Dent Med Probl.* 2004;41(3):549–552 [in Polish].
- [9] Mustafa MAE, Kurzawski M. Ortopedyczne metody ekspansji szczęki. *Dent Forum.* 2005;33(2):75–79 [in Polish].
- [10] Nowak R, Zawiślak E, Maks T. Wczesne efekty leczenia zwężenia szczęki metodą dystrakcji przezpodniebiennej. *Mag Stomatol.* 2013;23(6):56–60 [in Polish].
- [11] Pinto PX, Mommaerts MY, Wreakes G, Jacobs WV. Immediate postexpansion changes following the use of the transpalatal distractor. *J Oral Maxillofac Surg.* 2001;59(9):994–1000.
- [12] Suria L, Taneja P. Surgically assisted rapid palatal expansion: a literature review. *Am J Orthod Dentofac Orthop.* 2008;133(3):290–302.
- [13] Szarmach I, Bugała-Musiaticz B, Kalinowska M. Ocena zmian zębowych po zastosowaniu aparatu do szybkiego rozszerzania szczęki. *Dent Forum.* 2007;35(1):17–21 [in Polish].
- [14] Woods M, Wiesenfeld D, Probert T. Surgically-assisted maxillary expansion. *Aust Dent J.* 1997;42(1):38–42.