



Case Report

Management of giant myoma – case report and literature review

**Aleksandra Kamińska¹, Małgorzata Wojtas¹, Monika Ruszala²,
Tomasz Rechberger¹, Marek Gogacz¹**

¹ II Chair and Department of Gynecology, Medical University of Lublin, Lublin, Poland

² Chair and Department of Obstetrics and Perinatology, Medical University of Lublin, Lublin, Poland

ARTICLE INFO

Article history

Received: August 29, 2023

Accepted: October 6, 2023

Available online: October 20, 2023

Keywords

Chronic pelvic pain

Surgical treatment

Uterine tumors

Leiomyomas

Doi

<https://doi.org/10.29089/paom/173463>

User license

This work is licensed under a
Creative Commons Attribution –
NonCommercial – NoDerivatives
4.0 International License.



ABSTRACT

Introduction: Uterine myomas are one of the most frequently discussed issues in gynecology. Most of them are asymptomatic, however, severe pain in pelvis minor, heavy uterine bleeding or infertility may be reported by the patients and worsen quality of women's daily life. Giant myomas are very rare and can be directly life-threatening.

Aim: The aim of this study was to present a clinical case of giant myoma, its management and highlight the potential impact on women's health and well-being.

Case study: A 70-years-old patient with a pain in lower part of abdomen, constipation and tiredness manifested difficulties in breathing. Abdominal examination revealed a huge, elastic abdominal mass extending from xiphoid process to the pubic bone. A total abdominal hysterectomy with right salpingo-oophorectomy was done. The patient was discharged from the hospital on the day 9 after the surgery and recovered without any incident.

Results and discussion: Patients with giant uterine myomas may develop respiratory failure and require intensive respiratory care. One of the highest priorities should be adequate ventilation and reduction the vena cava compression. Cleansing the intestines before surgery decreases the risk of contamination the peritoneal cavity by digestive tract content, in case of possible extension of the scope of surgery.

Conclusions: In the case of treatment of large uterine myomas, interdisciplinary cooperation of specialists in various fields is necessary in order to protect the patient's vital parameters and prevent the occurrence of rare complications.

Corresponding author: *Monika Ruszala*; Chair and Department of Obstetrics and Perinatology,
Medical University of Lublin, Jaczewskiego 8, 20-090 Lublin, Poland.

E-mail address: monika.ruszala@wp.pl

1. INTRODUCTION

Do myomas really pose a serious gynaecological problem? It is reported that uterine fibroids occupy the first place among non-epithelial, benign tumors of the female reproductive organs.¹ In many communities around the world, little attention is paid to check-ups and prevention. In consequence there is delayed detection of lesions.²

Approximately 50%–77% of women may experience uterine myomas during their lifetime. Based on uterine fibroids location, they are distinguish as submucosal, intramural, subserosal, moreover, may be even pedunculated. Uterine myomas can develop anywhere within the uterine wall.^{3–6}

Large myomas can cause abdominal pressure, pain, constipation, increased frequency of micturition and urinary retention in the kidneys. They can also cause abnormal uterine bleeding, discomfort, bloating, anemia and dysmenorrhea. The above symptoms can significantly affect the quality of women's life and their daily functioning. They may contribute to lower productivity at work, distort self-image, disturb the interaction with friends and family. Due to the high recurrence of the disease, patients may feel negative emotions such as powerlessness, depression, stress related to hospitalization and operation which increases discomfort. All these situations may contribute to less satisfying intimate life; pain during intercourse, decreased, libido. This affects their relationship with the partner, stability of marriage and family. The disease restricts patient's activity and personal fulfilment. Another state worth paying attention is cosmetic aspect. Women with giant myomas, after successful operation may have excessive skin within abdominal wall. Stretched skin, reduced its tension as a negative consequence of the procedure may exacerbate depressive states and lead to dysmorphophobia.⁷

Giant myomas are usually rare, especially in developed countries.^{8,9} They may lead to the complications such as torsion, infarction or infection. Giant uterine leiomyomas may also be associated with mechanical obstruction of the venous system. Deep venous thrombosis and pulmonary thromboembolism are also reported as a complication of a large myoma as well as the myomatous erythrocytosis syndrome.¹⁰

The decision related to the implementation of a specific therapeutic method in a patient suffering from uterine fi-

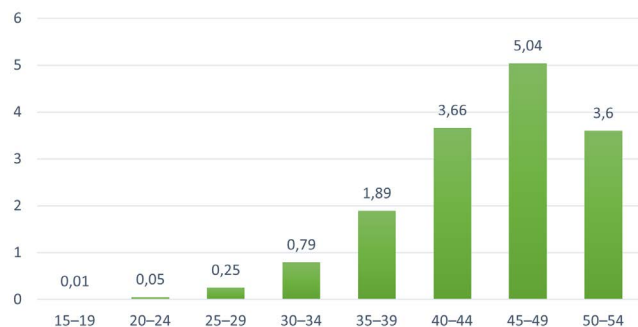


Figure 1. The risk of myomas in relation to age, per 1000 women in particular age groups.¹¹

broids should result from an individual case and be based on current health assessment, including: the number, size, type of change and reproductive plans. In the literature, surgical management is currently the first choice of myoma treatment lines.¹² It is estimated that about 75% of cases undergo hysterectomy, which is the final and irreversible method, preventing further formation of lesions.⁹

The golden standard in/of the treatment of uterine fibroids in young women is laparoscopic myomectomy in . Its advantages are: a shorter hospital stay, lower pain intensity and a better cosmetic effect compared to laparotomy.¹³ The most common operated are subserous and intermuscular fibroids. Submucosal lesions are removed by hysteroscopy. Intermuscular myoma surgery may contribute to further wall reconstruction depending on the number of layers. Laparoscopic resection is associated with a low risk of complications.^{14,15} Laparoscopic myomectomy should also not be performed if the lesion diameter is over 10 cm, when more than 3–4 fibroids are detected or when the sum of the diameter of enucleated fibroids exceeds 15 cm. Other alternative methods to keep the uterus are: embolization of the uterine arteries, ultrasound and radiofrequency wave therapy.^{16–18}

The treatment of huge uterine tumors in postmenopausal women poses a special challenge, especially if it is unknown how long the patient has had the huge uterine tumor in her pelvis and whether it grew before or after the menopause.¹⁴ Another problem is whether to recommend surgery, even if the tumor is thought to be a myoma uteri and will potentially diminish in size after the menopause.

2. AIM

The main aim of this study was to present rare case of giant myoma, its management and highlight the potential impact on women's health and well-being.

3. CASE STUDY

A patient who was 70 years old with a pain concentrated in lower part of abdomen, which has lasted for about 6 months was admitted to department of gynecology. The patient's personal history revealed difficulties in breathing, constipation and tiredness. In the past, the patient had left adnexectomy performed. Apart from that fact, her medical history was normal. Abdominal examination revealed a huge, elastic abdominal mass without tenderness extending from xiphoid process to the pubic bone. No abnormalities within external genitalia and uterine cervix were detected. The primary location of the tumor was hard to determine. Computed tomography examination revealed a large mass, approximately 32 × 34 × 37 cm in size, occupying the whole inferior abdomen without node swelling or distant metastases.

X-ray examination of the abdominal cavity and thorax showed the compressed lungs figure over the above-set diaphragm with smooth strokes and the heart supported by the

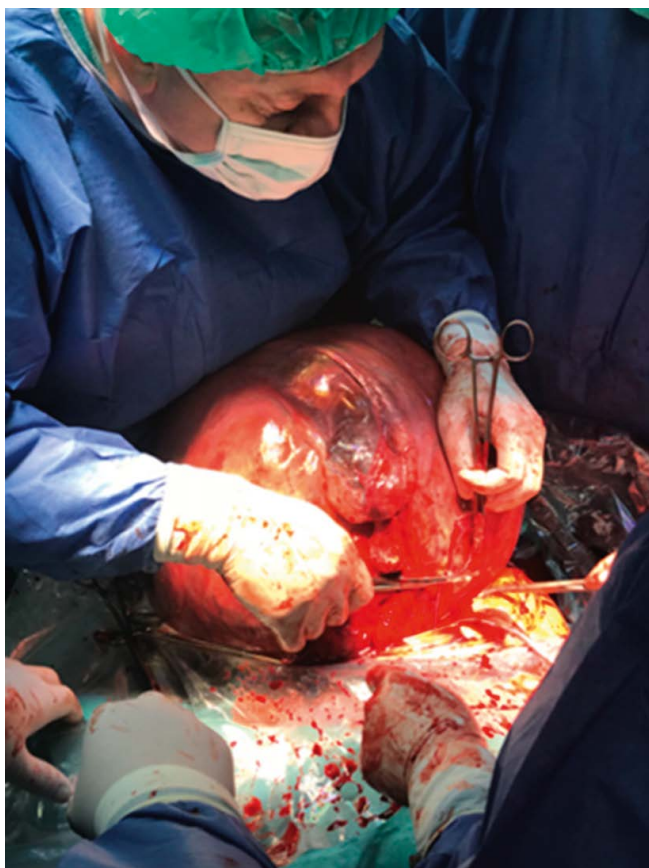

Figure 1. Intra-abdominal view of enlarged uterus.

tumor. No air was found under the diaphragm domes or fluid levels in the intestinal loops. Preoperative laboratory testing revealed an elevated level of red blood cell parameters (Hb 19.4 g/dL, RBC $6.33 \times 10^{12}/L$, HCT 58.3%) and Ca-125 105.3 U/mL. A haematological consultation was held. Because of increasing pain and difficulties with urination, defecation and breathing, the patient was qualified for laparotomy. Before the surgery, we asked for anesthetic consultation to protect the patient's vital functions. After the anesthesiological preparation of the patient, catheters were inserted into the right: radial artery, right internal jugular vein and right femoral vein. The surgeon was a gynecologic oncologist. An abdominal midline vertical incision was made and the huge tumor with a diameter of 35 cm arising from the uterus, stretching and modeling the abdominal wall, occupying the space from the pelvis to the diaphragm was observed. Two assistants were needed to lift and fix the giant tumor, secure the surgical field, and prevent vascular rupture. The myoma surface was smooth, hard, with many dilated veins.

The right ovary and other organs were without any macroscopic changes. Both ureters were found and followed. A total abdominal hysterectomy with right salpingo-oophorectomy was done and a drain was left in the Douglas pouch. The operation lasted about 70 minutes and blood loss was assessed to 1200 mL. The excised uterus with the tumor weighed 27 kg (Figures 1–3).

Because of the respiratory failure symptoms during the surgery, the patient was admitted to the Intensive Care Unit after

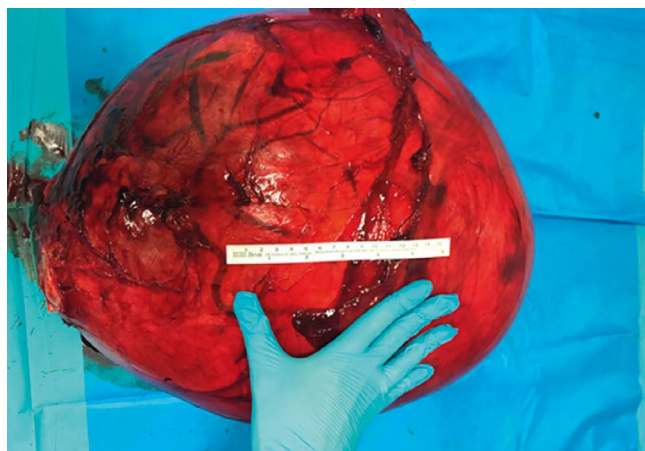


Figure 2. Excised uterus with giant myoma.

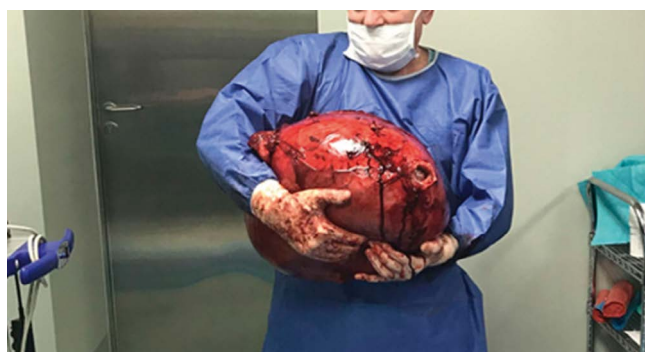

Figure 3. Presentation by the operator of removed uterus.

the procedure, where she was sedated and mechanically ventilated for one day. On the next day, the general condition of the patient was stable and she was transferred to gynecology department. Histopathological examination of the tumor revealed leiomyoma. The patient was discharged from the hospital on the day 9 after the surgery and recovered without any incident.

4. RESULTS AND DISCUSSION

Despite the benign nature of fibroids, putting the therapeutic decision aside and underestimating the problem may cause an increase in their dimensions, worsening the technical conditions of performing a possible surgery or lowering the quality of everyday life of the patient.¹⁹ Sufficient preparation of the patient and cooperation with many specialists are necessary for safe operation.

Pain is a commonly reported symptom that interferes with the daily functioning of the patients. There are two causes of the pain sensation: direct – as a case of dyspareunia/dysmenorrhea or indirect – by degeneration, torsion of a pedunculated fibroid or cervical dilation. Secondly reported is bleeding. Intraoperative blood loss, postoperative circulatory disorders, and abnormal coagulation may occur. To avoid these serious complications, for blood supply, 4 U of packed red blood cells and 2 U of fresh-frozen plasma were prepared. The operating team was in constant contact with the blood bank and transfusion laboratory.

Due to the anatomical proximity of the reproductive and urinary tracts and changes in the anatomy and position of organs caused by the presence of a large tumor in the pelvis, there is a huge risk of urinary tract injury during the surgery.²⁰ Due to large size of myomas patients suffer from overactive bladder, pollakiuria, nocturia subsequent hydro-nephrosis or pyelonephritis which in consequence may lead to renal dysfunction. Before the surgery we ask urologist for a consultation and assessed patient's renal parameters, that were at the lower limit of the norm. To avoid complications within urinary tract, ureteral catheters are used.²¹ In the case of our postmenopausal patient, there was no need for placement of a prophylactic ureteral catheter during surgery, because urethro-pyelography was performed before surgery.

Another problem worth paying attention is the myomatous erythrocytosis syndrome which depends on an excessive erythrocyte production, occurring in about 0.5% of individuals affected by uterine fibroids.²² This syndrome is believed to be caused by increased erythropoietin production by the kidneys or by the leiomyomas themselves.²³ To detect above syndrome, three conditions should be met: myomatus uterus, erythrocytosis, restoration and maintenance of normal hematological values after hysterectomy. This information is relevant for us in the case of our patient who had an elevated level of red blood cells parameters (Hb 19.4 g/dL, RBC $6.33 \times 10^{12}/L$, HCT 58.3%) and normal hematological values after surgery (Hb 12.7 g/dL, RBC $4.12 \times 10^{12}/L$, HCT 38.5%). A pressure caused by a tumor on the urinary outflow tract could induce erythropoietin elevation.²⁴

Compression of the large myoma into blood vessels can result in worsening the blood circulation and in consequence lead to very serious complications – deep venous thrombosis (DVT) and/or pulmonary thromboembolism (PTE). Fortunately, these conditions, associated with a uterine myoma, occur very rare.²⁵ In the case of DVT and PTE caused by a huge myoma, intravenous heparin and oral warfarin are administered before planned hysterectomy. The description in our case report stated that our patient had enoxaparin administered before and 30 days after the surgery to prevent vascular complications.

Being aware of hemodynamic effects and other clinical manifestations of huge fibroids may allow to face the problem more efficiently. Giant fibroids are a real challenge and require many intraoperative consultations between urologists, surgeons, gynecologists, oncologists and anesthesiologist. One of the highest priorities should be adequate ventilation and reduction the vena cava compression. The operating field should be suitably adjusted to easy manipulation of the mass of an abdomen. Although in recent years bowel cleansing before surgery has become less common, in our case we have decided to do the procedure due to no clear identification of tumor origin/another concomitant local disease processes. This step could prevent from contamination the peritoneal cavity by digestive tract content, lower risk of infection, wound complications, shorten the time of operation and improve its technical conditions in case of possible extension of the scope of surgery.

5. CONCLUSIONS

- (1) In the case of treatment of large uterine myomas, interdisciplinary cooperation of specialists in various fields is necessary in order to protect the patient's vital parameters and prevent the occurrence of rare complications.
- (2) Evolution of the disease may have a negative influence on the quality of life and social emotional well-being.
- (3) Many women are reluctant to ask for help and delay seeking treatment.
- (4) Minimizing certain symptoms such as weakness, chronic pelvic pain can develop into life-threatening.

Conflict of interest

None declared.

Funding

None declared.

References

- 1 Owayolu A, Filiz T, Savli T. A case of giant extra-uterine myxoid leiomyoma: An unusual benign pathology mimicking malignancy. *Pol Ann Med.* 2022;29(2):229–232. <https://doi.org/10.29089/paom/146658>.
- 2 Nappi L, Matteo M, Giardina S, Rosenberg P, Indraccolo U, Greco P. Management of uterine giant myoma. *Arch Gynecol Obstet.* 2008;278(1):61–63. <https://doi.org/10.1007/s00404-007-0523-1>.
- 3 Okamoto T, Koshiyama M, Yamamoto K. Treatment of huge uterine tumors thought to be benign in post-menopausal women. *Med Sci Monit.* 2004;10(2):43–45.
- 4 Aydin C, Eris S, Yalcin Y, Sen Selim H. A giant cystic leiomyoma mimicking an ovarian malignancy. *Int J Surg Case Rep.* 2013;4(11):1010–1012. <https://doi.org/10.1016/j.ijscr.2013.08.018>.
- 5 Frąckowiak L, Shafie D. Lipoleiomyoma of the uterus – a case report. *Pol Ann Med.* 2011;18(1):139–145. [https://doi.org/10.1016/S1230-8013\(11\)70033-9](https://doi.org/10.1016/S1230-8013(11)70033-9).
- 6 Yamamoto A, Suzuki S. Successful surgical treatment of a giant uterine leiomyoma: A case report. *Int J Surg Case Rep.* 2021;87:106416. <https://doi.org/10.1016/j.ijscr.2021.106416>.
- 7 Fellmann M, Battagay R, Rauchfleisch U, Mall-Haefeli M. Comparative socioeconomic, anamnestic and psychological studies of patients with uterine myoma and uterine prolapse [in German]. *Schweiz Arch Neurol Neurochir Psychiatr.* 1983;132(1):105–15.
- 8 Inaba F, Maekawa I, Inaba N. Giant myomas of the uterus. *Int J Gynaecol Obstet.* 2005;88(3):325–326. <https://doi.org/10.1016/j.ijgo.2004.12.026>.
- 9 Giuliani E, As-Sanie S, Marsh EE. Epidemiology and management of uterine fibroids. *Int J Gynecol Obstetrics.* 2020;149(1):3–9. <https://doi.org/10.1002/ijgo.13102>.

- ¹⁰ Nishikawa H, Ideishi M, Nishimura T, et al. Deep venous thrombosis and pulmonary thromboembolism associated with a huge uterine myoma. *J Vasc Dis*. 2000;51(2):161–166. <https://doi.org/10.1177/000331970005100210>.
- ¹¹ Martín-Merino E, Wallander MA, Andersson S, Montse Soriano-Gabarró M, Rodríguez LAG. The reporting and diagnosis of uterine fibroids in the UK: an observational study. *BMC Women's Health*. 2016;16:45. <https://doi.org/10.1186/s12905-016-0320-8>.
- ¹² Peker N, Gündoğan S, Şendağ F. Laparoscopic management of huge myoma nascendi. *J Minim Invasive Gynecol*. 2017;24(3):347–348. <https://doi.org/10.1016/j.jmig.2016.09.003>.
- ¹³ Milazzo GN, Catalano A, Badia V, Mallozzi M, Caserta D. Myoma and myomectomy: Poor evidence concern in pregnancy. *J Obstet Gynaecol Res*. 2017;43(12):1789–1804. <https://doi.org/10.1111/jog.13437>.
- ¹⁴ Vilos GA, Allaire C, Laberge P-Y, Leyland N. The management of uterine leiomyomas. *J Obstet Gynaecol Can*. 2015;37(2):157–178. [https://doi.org/10.1016/s1701-2163\(15\)30338-8](https://doi.org/10.1016/s1701-2163(15)30338-8).
- ¹⁵ Juhasz-Böss I, Jungmann P, Radosa J, et al. Two novel classification systems for uterine fibroids and subsequent uterine reconstruction after myomectomy. *Arch Gynecol Obstet*. 2017;295(3):675–680. <https://doi.org/10.1007/s00404-016-4268-6>.
- ¹⁶ Ji L, Jin L, Hu M. Laparoscopic myomectomy with temporary bilateral uterine artery occlusion compared with traditional surgery for uterine myomas: Blood loss and recurrence. *J Minim Invasive Gynecol* 2018;25(3):434–439. <https://doi.org/10.1016/j.jmig.2017.06.032>.
- ¹⁷ Keltz J, Levie M, Chudnoff S. Pregnancy outcomes after direct uterine myoma thermal ablation: Review of the Literature. *J Minim Invasive Gynecol*. 2017;24(4):538–545. <https://doi.org/10.1016/j.jmig.2017.01.009>.
- ¹⁸ Pisat S, van Herendael BJ. Temporary ligation of the uterine artery at its origin using a removable 'shoelace' knot. *J Minim Invasive Gynecol*. 2020;27(1):26. <https://doi.org/10.1016/j.jmig.2019.06.011>.
- ¹⁹ Stewart EA, Laughlin-Tommaso SK, Catherino WH, Lalitkumar S, Gupta D, Vollenhoven B. Uterine fibroids. *Nat Rev Dis Primers*. 2016;2:16043. <https://doi.org/10.1038/nrdp.2016.43>.
- ²⁰ Tanos V, Berry KE. Benign and malignant pathology of the uterus. *Best Pract Res Clin Obstet Gynaecol*. 2018;6:12–30. <https://doi.org/10.1016/j.bpobgyn.2017.10.004>.
- ²¹ Warda H. A trial placement of a prophylactic ureteral catheter during the excision of a huge pelvic mass with incidental cystotomy. *Cent Eur J Urol*. 2013;66:372–375. <https://doi.org/10.5173/cej.2013.03.art35>.
- ²² Toyama K, Mitus WJ. Experimental renal erythrocytosis. Relationship between the degree of hydronephrotic pressure and the production of erythrocytosis. *J Lab Clin Med*. 1966;68(5):740–752.
- ²³ Wrigley PFM. Secondary polycythaemia due to a uterine fibromyoma producing erythropoietin. *Br J Haematol*. 1971;21:551–555. <https://doi.org/10.1111/j.1365-2141.1971.tb02716.x>.
- ²⁴ Menzies DN. Fibromyomata and polycythaemia. *J Obstet Gynaecol Br Commonw*. 1961;68:505–509. <https://doi.org/10.1111/j.1471-0528.1961.tb02762.x>.
- ²⁵ Stanko CM, Severson MA 2nd, Molpus KL. Deep venous thrombosis associated with large leiomyomata uteri. A case report. *J Reprod Med*. 2001;46(4):405–407.