



## Research paper

# Use of point-of-care ultrasound in abdominal pain diagnostics in a paediatric patient

**Katarzyna Anna Szymak<sup>1,2</sup> , Michał Edward Bobrowicz<sup>1,2</sup>, Michał Tomasz Puliński<sup>1,2</sup> ,  
Wojciech Michał Choiński<sup>1,2</sup>, Natalia Hawryluk<sup>3</sup>**

<sup>1</sup> Department of Surgery, School of Public Health, Collegium Medicum, University of Warmia and Mazury in Olsztyn, Poland

<sup>2</sup> Clinical Ward of Paediatric Surgery and Urology, Regional Specialist Children's Hospital in Olsztyn, Poland

<sup>3</sup> Department of Family Medicine and Infectious Diseases, School of Medicine, Collegium Medicum, University of Warmia and Mazury in Olsztyn, Poland

## ARTICLE INFO

### Article history

Received: June 5, 2023

Accepted: October 11, 2023

Final review: November 10, 2023

### Keywords

POCUS

Point-of-care ultrasound

Abdominal pain

Emergency Department

Acute appendicitis

### Doi

<https://doi.org/10.29089/paom/174027>

### User license

This work is licensed under a Creative Commons Attribution – NonCommercial – NoDerivatives 4.0 International License.



## ABSTRACT

**Introduction:** The use of ultrasonography (USG) is no longer restricted to the radiology department. It is becoming the equivalent of a stethoscope. Point-of-care ultrasound (POCUS) is an USG examination method designed to answer specific clinical questions.

**Aim:** To encourage doctors to use POCUS in their everyday practice based on a presentation of its use in diagnostics of acute appendicitis in the paediatric patient.

**Material and methods:** A retrospective evaluation was performed of 95 cases of abdominal pain referred by a paediatrician for surgical assessment at emergency department between November 2021 and October 2022. The assessment included a clinical examination supplemented with POCUS.

Based on the assessment made by the emergency department doctor, the patients were divided into two groups – those who did not require hospitalisation in the paediatric surgery department (group 1) and those who did (group 2). Each group was subsequently divided into subgroup A, where no abdominal cavity USG was performed by a radiologist and subgroup B, where the patients were examined by a radiologist.

**Results and discussion:** The use of POCUS in the context of clinical symptoms allows for achieving the same degree of detectability as in an examination performed by a radiologist. A positive result of POCUS or clinical symptoms indicative of acute appendicitis requires continuing the diagnostic process.

**Conclusions:** The application of USG in abdominal pain diagnostics in a paediatric patient helps to reduce the time needed for the correct diagnosis and, in consequence, for the patient's treatment. Due to its availability, USG should be widely used to supplement clinical examination by each physician.

Corresponding author: Katarzyna Anna Szymak; Clinical Ward of Paediatric Surgery and Urology, Regional Specialist Children's Hospital in Olsztyn, Żołnierska 18a, 10-561 Olsztyn, Poland.

E-mail address: [kat.szymak@gmail.com](mailto:kat.szymak@gmail.com)

## 1. INTRODUCTION

The use of ultrasonography (USG) used to be limited to the radiology department. The current wide availability of ultrasonography equipment in nearly every hospital ward or outpatient clinic creates not only an opportunity, but even an obligation, for a physician to use it in everyday practice. The USG apparatus has become the stethoscope of the 21st century. Not using the USG technique seems to be tantamount to deliberately giving up the best diagnostic option available to the patient: cheap, safe, easily available – here and now. Point-of-care ultrasound (POCUS) is a method of USG examination which is supposed to answer specific clinical questions. The idea behind this examination is that it can be performed by a physician who is not a specialist in imaging diagnostics.<sup>1</sup> It becomes a coherent part of the interview with the patient and physical examination. Being complementary to clinical examination, POCUS helps to improve clinical effectiveness at a level comparable to an examination conducted by a radiologist.<sup>2</sup> It does not replace a radiographic examination, as it is not the clinician's task to perform a full examination of a specific anatomical area.<sup>3</sup> It becomes necessary to supplement the diagnostics with a radiological examination in case of uncertainty, also in the use of such diagnostic methods as magnetic resonance imaging (MRI) or computed tomography (CT) scans.<sup>2</sup> POCUS should be of particular use when a radiologist is not available – when only emergency personnel is present or in outpatient practice.

An USG examination is not objective. Its result depends on the operator's experience and qualifications. Lack of experience often creates a barrier discouraging one from using this diagnostic tool. A study conducted by Blehar et al. showed that the operator's experience increased with the number of procedures performed. The POCUS learning curve soon reaches its peak.<sup>4</sup> Training in POCUS and the possibility of adding USG to the clinical assessment tools gives a doctor better decision-making capabilities and makes the diagnostic and treatment process more efficient.<sup>5</sup> Current online training opportunities also facilitate access to this knowledge.<sup>6</sup>

Abdominal pain remains one of the most frequent causes of surgery consultations in the emergency department (ED).<sup>2</sup> Approximately 7% of patients with acute abdominal pain are those with acute appendicitis.<sup>7</sup> Differential diagnostics of abdominal pain at ED can be a challenge. The use of uUSG helps to dispel many doubts. The sensitivity of a sonographic examination in diagnosing appendicitis lies within the range of 80%–95%, and its specificity is 90%–100%.<sup>8</sup> Not performing an USG examination may prolong the time needed for making the correct diagnosis, thereby increasing the risk of complications.<sup>2</sup> POCUS in appendicitis diagnostics improves its detection capability, especially with specific clinical symptoms. According to the literature review performed by Benabbas et al., the sensitivity of POCUS performed by an emergency medicine doctor in detecting appendicitis was 86%, and its specificity was 91%, which makes POCUS a good predictor for acute appendicitis. In

contrast, negative POCUS considerably reduces the probability of this condition.<sup>2</sup> Adding POCUS to the physical examination and laboratory test results in an increase in acute appendicitis detectability from 42.8% to 87.0% with a positive POCUS, and a decrease in the condition probability from 42.8% to 11.0% with a negative POCUS.<sup>2</sup>

The aim of USG is to try to find other sources of pain than acute appendicitis, which helps to properly manage the diagnostics and treatment process. This is essential from the surgeon's perspective as it helps to determine the surgery duration, its urgency and the method of operative access.

## 2. AIM

The aim of this study is to encourage doctors to use POCUS in their everyday practice based on a presentation of its use in the diagnostics of acute appendicitis in a paediatric patient.

## 3. MATERIAL AND METHOD

A retrospective evaluation was performed of 95 cases of non-traumatic abdominal pain referred by a paediatrician for surgical assessment at the ED between November 2021 and October 2022. The assessment included a clinical examination supplemented with POCUS. All the patients were examined by the same physician.

The examinations were performed at the ED. The examinations were performed mainly with a Philips HD11XE apparatus with Convex 4–9 MHz, Microconvex 5–8 MHz heads and a linear 3–12 MHz head, and with a Samsung HS40 with the 3–16MHz linear head and Convex 2–8MHz and Microconvex 4–9 MHz.

In order to systematise the cases based on the assessment made by the ED doctor, the patients were divided into two groups – those who did not require hospitalisation in the paediatric surgery department (group 1) and those who did (group 2). Each group was subsequently divided into subgroup A, where no abdominal cavity USG was performed by a radiologist and subgroup B, where the patients were examined by a radiologist. The algorithm of classification into groups is shown in Figure 1.

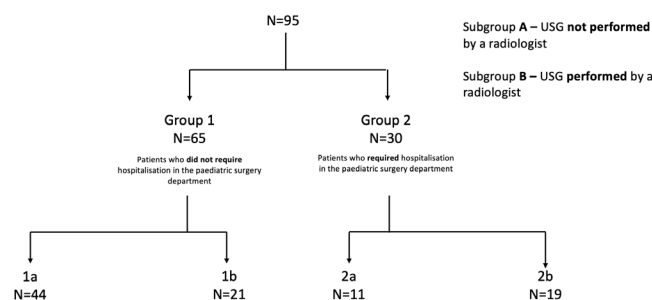


Figure 1. Algorithm for the division of the study group.

The patients in each group were assessed for specific clinical symptoms:

- peritoneal symptoms,
- abdominal guarding,
- soft abdomen in a clinical examination.

The POCUS examination included examining abdominal cavity organs with a convex or micro-convex head, depending on the child's age and body weight, according to the following pattern:

- assessment of fluid presence in the abdominal cavity according to the e-FAST (extended focused assessment with sonography for trauma) algorithm,
- epigastrium assessment – including the pancreas and the liver with its cavity,
- assessment of the right flank – liver, gallbladder and the right kidney,
- assessment of the left flank – spleen, tail of the pancreas and the left kidney,
- assessment of hypogastrium and pelvis minor through the suprapubic area – bladder, rectum, uterus with appendages and prostatic gland.

Subsequently, an examination with the linear head was performed. The examination was performed of the whole abdominal cavity and the retroperitoneal area. Particular attention was devoted to an assessment of the right fossa iliaca in search of the appendix. If required by the patient, each examination was supplemented with a specific inspection of the specific area/organ.

A total of 95 patients were enrolled – 52 girls and 43 boys, aged between 1 month and 17 years, with a median age of 13 years (Figure 2).

The follow-up period ranged from 2 weeks to 12 months.

#### 4. RESULTS AND DISCUSSION

Group 1 included 65 patients. Subgroup 1A – those not admitted to the surgery department and not examined by a radiologist – included 44 patients. A soft abdomen in a clinical examination was found in all of these patients. PO-

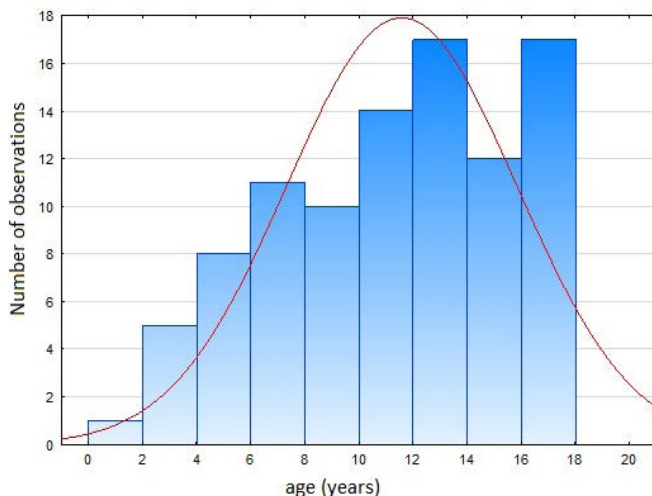


Figure 2. Age profile of patients in the study group.

CUS usually revealed retroperitoneal lymph node enlargement and semi-liquid chyme in the intestines, which could be indicative of diarrhoea. The USG examination revealed no anomalies in the majority of the patients. None of the patients required hospitalisation in the paediatric surgery ward during the follow-up.

Subgroup 1B – those not admitted to the surgery department but examined by a radiologist – included 21 patients. A soft abdomen in a clinical examination was found in all those patients. POCUS usually revealed the presence of enlarged retroperitoneal lymph nodes, no anomalies, and thickening of the bowel loop. These symptoms were also usually revealed in a radiological USG examination. There is no statistically significant difference in the detection of individual symptoms between POCUS and a radiographic examination (Table 1). None of the patients required hospitalisation in the paediatric surgery ward during the follow-up.

Group 2 included 30 patients. Subgroup 2A – those admitted to the surgery department and not examined by a radiologist – included 11 patients. POCUS revealed an inflamed appendix in eight of them, and signs of paralytic intestinal obstruction, which is an indirect symptom of acute appendicitis, was observed in one of them. Coprolite in the appendix was revealed in two patients. A focal lesion of an ovary was found in one patient. All of the patients underwent surgery, ten because of acute appendicitis, and one patient underwent laparoscopic reduction of the ovarian torsion after the diagnosis was confirmed with MRI. Among the patients who underwent appendectomy, 90% had signs of abdominal guarding, and 70% had peritoneal symptoms. The patient with ovarian torsion had a soft abdomen.

Table 1. Incidence of ultrasonographic symptoms in POCUS and in radiological USG in group 1B, which included patients not admitted to the surgery department and examined by a radiologist. Evaluation of the statistical significance of the difference in finding them between those two examinations.

Symptoms	POCUS n(%)	Radiological USG n(%)	Bilateral Fisher test P
No lesions	7(33)	4(19)	0.48
Focal lesion in an ovary	1(5)	1(5)	1.0
Abdominal tumour	1(5)	1(5)	1.0
Rectal dilation – constipation	1(5)	0(0)	1.0
Signs of dehydration (IVC assessment)	1(5)	0(0)	1.0
Bowel loops filled with semi-liquid chyme (diarrhoea)	2(10)	0(0)	0.49
Thickened bowel loop	4(19)	3(14)	0.70
Focal lesion in a kidney	0(0)	1(5)	1.0
Exposed appendix	1(5)	1(5)	1.0
Liquid in abdominal cavity	2(10)	0(0)	0.49
Dilation of the pelvicalyceal system	2(10)	2(10)	1.0
Nephrolithiasis	1(5)	1(5)	1.0
Cholelithiasis	1(5)	1(5)	1.0
Hepatomegaly	0(0)	2(10)	0.49

**Table 2. Incidence of ultrasonographic symptoms in POCUS and in radiological USG in group 2B, which included patients admitted to the surgery department and examined by a radiologist. Evaluation of the statistical significance of the difference in finding them between those two examinations.**

Symptoms	POCUS n(%)	Radiological USG n(%)	Bilateral Fisher test P
No lesions	5(26)	2(11)	0.40
Focal lesion in an ovary	2(11)	3(16)	1.0
Bowel loops filled with semi-liquid chyme (diarrhoea)	2(11)	0(0)	0.49
Thickened bowel loop	0(0)	1(5)	1.0
Focal lesion in a kidney	1(5)	2(11)	1.0
Exposed appendix	5(26)	4(21)	1.0
Appendix exposed over 6 mm	5(26)	4(21)	1.0
Liquid in abdominal cavity	7(37)	3(16)	0.27
Coprolite	1(5)	0(0)	1.0
Lymph nodes	3(16)	7(37)	0.27
Dilation of the pelvicalyceal system	2(11)	0(0)	0.49
Nephrolithiasis	1(5)	1(5)	1.0
Cholelithiasis	2(11)	2(11)	1.0
Pyloric stenosis	1(5)	1(5)	1.0
Splenomegaly	0(0)	1(5)	1.0
Overflowing peristalsis	1(5)	0(0)	1.0

Subgroup 2B – those admitted to the surgery department and examined by a radiologist – included 19 patients. The most frequent symptoms in POCUS included: fluid in the abdominal cavity, appendix over 6 mm in diameter, no changes in the USG examination, enlarged retroperitoneal lymph nodes, and a focal lesion in an ovary. These symptoms were also observed in the radiological USG examination. There is no statistically significant difference in the detection of individual symptoms in USG between the examination performed by a surgeon and by a radiologist (Table 2). In this subgroup, 9 (47%) patients underwent surgery, including 5 (26%) who underwent appendectomies. Apart from an appendectomy, procedures performed included laparoscopic cholecystectomy (in 2 patients), pyloromyotomy, and reduction of ovarian torsion.

To summarise the procedures performed in these groups – patients with negative POCUS but with clinical symptoms of acute appendicitis, or with positive POCUS but with no symptoms, were admitted to the surgery department or had radiological USG performed to supplement the diagnostics. Bachur et al.<sup>9</sup> made an attempt to integrate the clinical, radiographic and laboratory picture of patients with suspected acute appendicitis. The findings of their study suggest that patients with a high paediatric appendicitis score (PAS) but with a negative result in the POCUS examination and with low PAS, but positive POCUS, require further diagnostics. Additionally, according to literature reports, repeatable results of USG examina-

tions give a better outcome in appendicitis diagnostics due to a possible change of the ultrasound picture with the duration of abdominal pain.<sup>10</sup>

There was no statistically significant difference between the presence of individual USG symptoms in POCUS and in a radiological examination. The valuable knowledge provided by the clinical trial allows for the correct interpretation of the POCUS picture, which gives an effect of comparable effectiveness of visualisation of specific USG symptoms as in a radiographic examination.<sup>2</sup>

The sensitivity of POCUS in detecting acute appendicitis in these results is 87%, based only on the symptom ‘revealing an appendix with the diameter over 6 mm.’ When indirect symptoms are taken into account, it is 93%. According to literature reports, the sensitivity of a USG examination in detecting appendicitis is 80%–95%, and its specificity is 90%–100%.<sup>8</sup> It is also important that all the patients who required surgery were admitted to the surgery department, which prevented a patient with appendicitis from being discharged from the hospital.

There is an interesting case among these patients – a 17-year-old boy in group 2A, whose POCUS results – apart from signs of acute appendicitis – allowed for suspecting a focal lesion in the right kidney. The USG examination performed by a radiologist confirmed the suspicion. The patient underwent laparoscopic appendectomy, and an MRI examination was performed for kidney diagnostics during the post-operative hospitalisation. The MRI scan excluded a focal lesion of the left kidney. An USG examination allows for diagnosing not only the patient’s current acute problem but also other chronic conditions, which affect the surgeon’s decisions during an operation, methods used to perform it or performing additional diagnostics before it.<sup>7</sup> POCUS is only a supplementary, additional examination. Alone it is not decisive. However, it allows for managing the diagnostics and treatment process properly, with all the patient’s needs taken into account.

## 5. CONCLUSIONS

- (1) The application of USG in abdominal pain diagnostics in a paediatric patient helps to reduce the time needed for the correct diagnosis and, in consequence, for the patient’s treatment.
- (2) Due to its availability, USG should be widely used to supplement a clinical examination by each physician.

## Conflict of interest

None declared.

## Funding

None declared.

## References

- <sup>1</sup> Mollenkopf M, Tait N. Is it time to include point-of-care ultrasound in general surgery training ? A review to stimulate discussion. *ANZ J Surg.* 2013;83(12):908–911. <https://doi.org/10.1111/ans.12363>.
- <sup>2</sup> Benabbas R, Hanna M, Shah J, Do RS. Diagnostic Accuracy of History, Physical Examination , Laboratory Tests , and Point- of-care Ultrasound for Pediatric Acute Appendicitis in the Emergency Department : A Systematic Review and Meta-analysis. *Acad Emerg Med.* 2017;24(5):523–551. <https://doi.org/10.1111/acem.13181>.
- <sup>3</sup> Avinadav E, Almog A, Kravarusic D, et al. Point-of-Care Ultrasound in a Department of Pediatric and Adolescent Surgery. *Isr Med Assoc J.* 2016;18(11):677–679.
- <sup>4</sup> Blehar DJ, Barton B, Gaspari RJ. Learning Curves in Emergency Ultrasound Education. *Acad. Emerg. Med.,* 2015;22(5):574–582. <https://doi.org/10.1111/acem.12653>.
- <sup>5</sup> Moses A, Weng W, Orchanian-Cheff A, Cavalcanti RB. Teaching Point-of-Care Ultrasound in Medicine. *CJGIM.* 2020;15(2):13–29. <https://doi.org/10.22374/cjgim.v15i2.368>.
- <sup>6</sup> Eduson.pl. [www.eduson.pl](http://www.eduson.pl). Accessed: June 10, 2023.
- <sup>7</sup> Soundappan SS, Karpelowsky J, Lam A, Lam L, Cass D. Diagnostic accuracy of surgeon performed ultrasound (SPU) for appendicitis in children. *J Pediatr Surg.* 2018;53(10):2023–2027. <https://doi.org/10.1016/j.jpedsurg.2018.05.014>.
- <sup>8</sup> Marilyn J. Siegel. *Peadiatric utrasonography* [in Polish]. Warsaw: MediPage; 2012:366–373.
- <sup>9</sup> Bachur RG, Callahan MJ, Monuteaux MC, et al. Integration of ultrasound findings and a clinical score in the diagnostic evaluation of pediatric appendicitis. *J Pediatr.* 2015;166(5):1134–1139.
- <sup>10</sup> Glass CC, Rangel SJ. Overview and diagnosis of acute appendicitis in children. *Semin Pediatr Surg.* 2016;25(4):198–203. <https://doi.org/10.1053/j.sempedsurg.2016.05.001>.