



Case Report

Antiphospholipid syndrome associated with sicca syndrome

Avni Kryeziu^{1,2}, Shend Kryeziu³, Fatlinda Berisha³

¹ Rheumatology Clinic, University Clinical Center of Kosovo, Prishtina, Kosovo

² Alma Mater Europa, Campus College 'Rezonanca,' Prishtina, Kosovo

³ Faculty of Medicine, University of Prishtina 'Hasan Prishtina,' Prishtina, Kosovo

ARTICLE INFO

Article history

Received: August 3, 2024

Accepted: October 8, 2024

Available online: February 13, 2025

Keywords

Antiphospholipid syndrome

Autoimmune

Sicca syndrome

Doi

<https://doi.org/10.29089/paom/194250>

User license

This work is licensed under a Creative Commons Attribution – NonCommercial – NoDerivatives 4.0 International License.



ABSTRACT

Introduction: Antiphospholipid syndrome (APS), or antiphospholipid antibody syndrome, is an autoimmune, hypercoagulable condition caused by antiphospholipid antibodies.

Aim: This case study aims to highlight diagnostic challenge of APS and its association with sicca syndrome.

Case study: Our case is a female patient who was transferred to Rheumatology Clinic from the Central Intensive Care Unit (CICU) after being unconscious and on assisted breathing for 5 days. In 2006, she suffered a miscarriage and pulmonary thromboembolism. Since then, she has been under anticoagulant treatment. Clinical observation and positivity of laboratory tests such as anti Ro SSA, anti La SSB and Schirmer test confirmed us sicca syndrome. Positivity of lupus anticoagulant, anti-cardiolipin and anti-B2GP1 raise us suspicious about APS. The patient stayed in our clinic for approximately 10 days and based on the anamnesis, objective examination, laboratory and imaging tests, she was discharged home with the diagnosis of APS accompanied by sicca syndrome.

Results and discussion: APS is an autoimmune condition, often challenging to diagnose, especially when it occurs in patients without sufficient symptoms and signs and without positivity in blood tests. The diagnosis of APS is often made through a combination of symptoms and laboratory tests.

Conclusions: Diagnosing APS is not always easy, it is quite complex. Any case associated with spontaneous abortion and vascular accidents, without risk factors, should be suspected and investigated for APS. APS can often be secondary associated with other autoimmune diseases. Most often APS is associated with systemic lupus erythematosus, but in our case it is associated with sicca syndrome.

1. INTRODUCTION

Antiphospholipid syndrome (APS), or antiphospholipid antibody syndrome, is an autoimmune, hypercoagulable condition caused by antiphospholipid antibodies. This syndrome can lead to blood clots (thrombosis) in the arteries and veins, pregnancy-related complications, and other symptoms such as low platelet counts, kidney disease, heart disease, etc. Although the exact etiology of APS is not clear yet, genetics are believed to play a key role in the development of the disease.¹ Diagnosis is based on symptoms and blood tests. Criteria for investigation of APS are based on a clinical event (i.e., thrombosis or pregnancy complications) and two positive blood test results at least 3 months apart, including lupus anticoagulant, anti-apolipoprotein antibodies, and /or anti-cardiolipin antibodies.² APS can be primary or secondary. Primary APS occurs in the absence of any other disease, i.e. as the only one. Secondary APS appears associated with other autoimmune diseases, such as systemic lupus erythematosus (SLE) and other diseases. In rare cases, APS leads to rapid organ failure due to generalized thrombosis. This condition is called 'catastrophic antiphospholipid syndrome' (Asherson syndrome) and is associated with a high risk of death. APS often requires treatment with anticoagulant drugs to reduce the risk of further thrombotic episodes and improve prognosis in pregnant women. Anticoagulant drugs used for treatment may vary depending on the circumstances, such as pregnancy. APS is known to cause arterial or venous blood clots in any organ system and pregnancy-related complications. While thromboses and pregnancy complications are the most common and diagnostic symptoms associated with APS, other tissues and organs such as decreased platelet counts, the heart, kidneys, brain and skin can also be affected.³ Also, patients with APS may have symptoms associated with other autoimmune diseases that are not caused by APS since APS can occur at the same time as other autoimmune diseases. APS is an autoimmune disease in which 'antiphospholipid antibodies' react against proteins that bind to anionic phospholipids in plasma membranes. Anti-cardiolipin, β 2-glycoprotein 1 and lupus anticoagulant antibodies are antiphospholipid antibodies that are thought to cause disease clinically. These antibodies lead to blood clotting and vascular disease in the presence (secondary APS) or absence (primary APS) of other diseases.⁴ While the exact functions of the antibodies are unknown, activation of the coagulation system is evident. Other antibodies associated with APS include antibodies against protein S and annexin A5. Protein S is a cofactor of protein C, which is one of the body's anticoagulant factors. Annexin A5 forms a shield around negatively charged phospholipid molecules, which reduces the membrane's ability to participate in coagulation. Thus, antibodies against protein S and annexin A5 decrease the efficacy of protein C and increase the phospholipid-dependent coagulation steps, respectively, leading to increased coagulation potential.^{5,6} Patients with lupus anticoagulant antibodies combined with moderate or high titer anti-cardiolipin antibodies show a greater risk of

thrombosis than with either alone. Increased risks of recurrent miscarriage, intrauterine growth restriction, and preterm birth from antiphospholipid antibodies, as supported by *in vitro* studies, include decreased trophoblast viability, hormonal disruption, and trophoblast signaling molecules.⁷

2. AIM

This case study aims to highlight the diagnostic challenges of antiphospholipid syndrome in a female with chronic vascular accidents and its association with other autoimmune diseases.

3. CASE STUDY

Our case is a female patient who was transferred from the Central Intensive Care Unit (CICU) after being unconscious and on assisted breathing for 5 days. In fact, the patient refers that in 2006 she suffered a spontaneous abortion and pulmonary thromboembolism. Since then, she has been under anticoagulant treatment. Now, 3 months before being admitted to CICU, the patient had dizziness, fatigue and occasional deconcentration that lasted several minutes. Due to these complaints, she consulted with the neurologist who had recommended the continuation of anticoagulant treatment. On the critical night, the patient lost consciousness during sleep and was immediately transferred to the University Clinical Center of Kosovo (UCCK) where she was hospitalized in the CICU. During her stay at CICU, the patient underwent laboratory tests and imaging examinations which resulted in the following: leukocytes were at normal values, erythrocytes were at slightly low levels (mild anemia), platelets were also normal, inflammatory reactants were normal, liver and kidney function tests were also normal, serum proteins were somewhat lower. Regarding autoimmune tests: ANA was positive (ANA=2.4 COI), anti dsDNA was negative, anti Ro SSA was positive (above 100 AU/mL), anti La SSB was positive (above 100 AU/mL), anti-cardiolipin was positive (over 100 GPLU/mL), lupus anticoagulant was positive, anti RNP was negative, anti B2GPI was positive (62.8 AU/ml), as it is shown in Table 1. Direct and indirect Coombs were normal and blood coagulation tests were also normal: prothrombin time (PT) was 91% (ref. >70%); partial thromboplastin time (PTT) was 25 s (ref. 25–35 s); thrombin time was 14 s (ref. 12–19 s). No abnormality in coagulation system were observed despite the presence of lupus anticoagulant and antiphospholipid antibodies. In the CT performed during the stay at CICU, signs of ischemia in the brain parenchyma of chronic and subacute nature were seen. After being transferred to the Rheumatology Clinic, the patient was now better, conscious, breathing spontaneously, but still fatigued. From taking the anamnesis, the patient refers that, among other things, she also had problems with a lack of secretions, that is, she had a problem with lack of tears, saliva and genital secretions. She also had joint pain, mostly in hands and

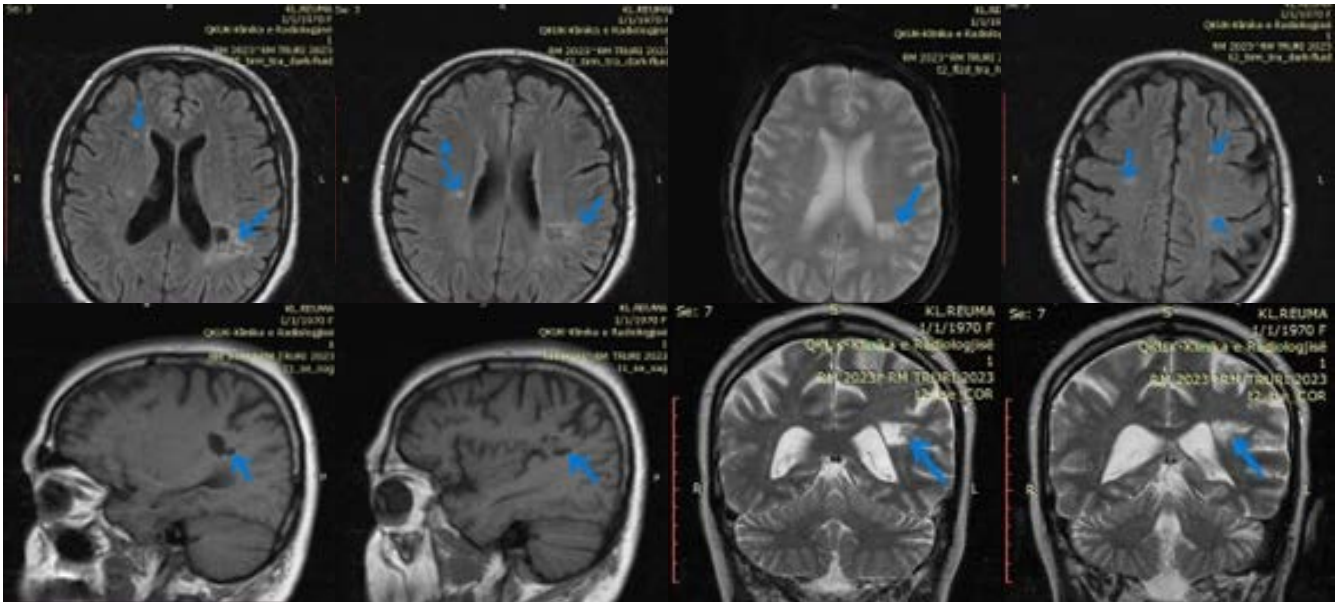


Figure 1. MRI of the head with signs of chronic ICV, signs of subacute ischemia and mild cerebral atrophy. Chronic ischemic changes are seen in the left parietal periventricular region with dimensions of about 12 mm. A millimetric (3.5 mm) paraventricular lesion is also seen in the right frontal white mass, which corresponds to a subacute lesion. In the periventricular region and in the bilateral frontoparietal deep white matter, millimetric lesions are seen that respond to gliotic changes as a consequence of chronic microvascular disease.

knees. Schirmer test was also positive. We repeated blood tests where mild anemia was still present. When we saw that there were problems with the presence of specific antibodies, we suspected that it was APS and in addition to anticoagulant therapy (fraxiparin 6 mg twice a day) we also started treatment with corticosteroids in doses of 1 mg per 1 kg of body weight (80 mg). We also performed magnetic resonance of the head to investigate the brain parenchyma. The brain MRI result showed signs of chronic ICV and signs of subacute ischemia in the right frontal region. Mild cerebral atrophy was also seen. The right optic nerve was presented tortuously Figure 1.

During her stay at the Clinic, the patient was also given additional consultations and examinations by cardiologist, hematologist, pulmonologist and gynecologist. In the hematological aspect, the patient had a mild form of anemia. Cardiologically, the patient had arterial hypertension as well as an asymmetric hypertrophy with preserved systolic function. From the pulmonary point of view, the patient had some pulmonary changes in the form of reticulo-nodular shadows on the right and a load in the interstitium. As for

the gynecological aspect, the patient had no pathological features. The patient stayed in our Clinic for approximately 10 days and based on the anamnesis, objective examination, laboratory and imaging tests, she was discharged home with the diagnosis of APS accompanied by sicca syndrome. She was released with anticoagulant therapy (Sinthrome 4 mg tablets once daily), a maintenance dose of corticoids (40 mg) with the recommendation to reduce the dose week by week, vitamin therapy and for the first time we included the modifying, antimalarial therapy (hydroxychloroquine) according to the protocol. We also recommended her after 1 month to report to us in the control to monitor the condition of the patient and the effect of the drugs.

4. DISCUSSION

APS is an autoimmune condition, often challenging to diagnose, especially when it occurs in patients without sufficient symptoms and signs and without positivity in blood tests. The diagnosis of APS is often made through a combination of symptoms and laboratory tests. Repeat of antibody testing 12 weeks after detection of the presence of antiphospholipid (aPL) antibodies is necessary to establish the diagnosis, because false positives can occur.^{2,8,9}

Our case was a patient with a long history of complaints including the presenting symptoms and signs for which she had been treated. In 2006, she suffered an unexplained miscarriage and a few days later suffered a pulmonary embolism, for which she was treated with anticoagulants. Also, later she started having problems with the lack of secretions, such as lack of tears and conjunctivitis from time to time,

Table 1. Results of autoimmune tests

Analyse type	Value	Referent value
ANA screen	2.4 COI	<1.2 COI
Anti Ro SSA	>100 AU/mL	<18 AU/mL
Anti La SSB	>100 AU/mL	<18 AU/mL
Lupus anticoagulant	95.5 s	30–50 s
Anticardiolipin	>100 GPLU/mL	<18 GPLU/mL
Anti G2BP1	62.8 AU/mL	<18 AU/mL

lack of fluids in the mouth and genitals and was treated with symptomatic therapy (artificial tears and adequate lubricant). Despite the aforementioned complaints, until now there has not been an accurate diagnosis, but only a symptomatic diagnosis, without knowing the exact cause of these complaints. So it took more than 18 years for her to be diagnosed and begin adequate treatment.

While APS was previously categorized into primary and secondary based on the absence or presence of concomitant autoimmune disease, the 16th International Congress of the Task Force on Antiphospholipid Antibodies categorizes APS into 6 categories: the first has no clinical symptoms in the presence of antiphospholipid antibodies, the second is related to pregnancy, the third is related to blood clotting (venous or arterial), the fourth is microvascular (small blood vessels), the fifth is catastrophic and the sixth is not related to blood clotting (i.e. the form that affects the kidneys, low blood platelets, heart valve disease). In their report, they acknowledge that some individuals may qualify for more than one category based on the symptoms and signs they exhibit.³

Our case had involvement of blood vessels, there were pregnancy complications where she suffered a spontaneous abortion many years ago and in the blood tests there was positivity in most of the antibodies present in the serum. According to the categorization by the antiphospholipid antibody task force, our case had many symptoms and signs and therefore it can be classified into many categories, except in the category as a form of catastrophic APS.

APS can be associated with other autoimmune diseases, most often with SLE, but rarely with other diseases such as dry syndrome or sicca syndrome.

Sicca syndrome, also known as Sjogren's syndrome, is a rare systemic autoimmune disorder associated with pregnancy disorders with a prevalence of 0.3–0.6%.¹⁰

In the patient of the case under study, over time, the complaints related to the lack of secretions also started, that is, there was an insufficiency of the glands with external secretion such as the lacrimal gland, the salivary gland, the glands of the genital organs, where as a result the patient had conjunctivitis dryness, repeated dry mouth (xerostomia) as well as dryness of the genital tract. After laboratory examinations, specific tests such as anti RoSSA and anti LaSSB were also found positive in her. Thus, the presence of sicca syndrome (Sjogren's syndrome) accompanying APS was confirmed.

In a paper reported by Flores et al., a case with neurological signs and sicca syndrome was described. After the analysis, a positive titer of anti RoSSA, anti La SSB, lupus anticoagulant and the presence of antiphospholipid antibodies were found. Clinical tests for dry syndrome were also positive. After it was confirmed that the patient had APS associated with dry syndrome, treatment with glucocorticoids, cyclophosphamide, antiepileptics and anticoagulants was started, which were very successful. This presentation of this case underlines the importance of suspecting this pathology in young patients with vascular and central nervous system compromise.¹¹

After the patient's hospitalization in our clinic and after the diagnosis, we immediately started corticoid treatment with a dose of 1 mg per 1 kg body weight (80 mg) and with anticoagulant therapy, fraxiparin 6 mg twice a day as well as disease modifier (hydroxychloroquine 200 mg), after which the patient's health improved significantly. She was discharged in very good health, without any neurological deficit, recommending to continue the therapy with cortisone 40 mg per day, anticoagulant, as well as disease modifier hydroxychloroquine in a dose of 200 mg per day.

5. CONCLUSIONS

1. Diagnosing APS is not always easy, in fact it is quite complex, therefore it requires dedication and a lot of attention.
2. Any case associated with spontaneous abortion and vascular accidents, without risk factors, should be suspected and investigated for APS.
3. APS can often be secondary, so it can be associated with other autoimmune diseases.
4. Most often, APS is associated with SLE, but in our case it was associated with dry syndrome (Sjogren).

Conflict of interest

None declared.

Funding

None declared.

Acknowledgements

We would like to show our gratitude to the Rheumatologic Clinic for sharing their pearls of wisdom with us during the course of this research, and we thank our reviewers for their so-called insights.

References

- 1 Islam MA, Khandker SS, Alam F, Kamal MA, Gan SH. Genetic risk factors in thrombotic primary antiphospholipid syndrome: A systematic review with bioinformatic analyses. *Autoimmun Rev.* 2018;17(3):226–243. <https://doi.org/10.1016/j.autrev.2017.10.014>.
- 2 Barbhaiya M, Zuily S, Naden R, et al. The 2023 ACR/EULAR Antiphospholipid Syndrome Classification Criteria. *Arthritis Rheumatol.* 2023;75(10):1687–1702. <https://doi.org/10.1002/art.42624>.
- 3 Sciascia S, Radin M, Cecchi I, Levy RA, Erkan D. 16th International congress on antiphospholipid antibodies task force report on clinical manifestations of antiphospholipid syndrome. *Lupus.* 2021;30(8):1314–1326. <https://doi.org/10.1177/09612033211020361>.

- ⁴ Asiful Islam Md, Alam F, Haryo Sasongko T, Hua Gan S. Antiphospholipid antibody-mediated thrombotic mechanisms in antiphospholipid syndrome: Towards pathophysiology-based treatment. *Curr Pharm Des.* 2016;22(28):4451–4469. <https://doi.org/10.2174/1381612822666160527160029>.
- ⁵ Triplett DA. Antiphospholipid antibodies. *Arch Pathol Lab Med.* 2002;126(11):1424–1429. <https://doi.org/10.5858/2002-126-1424-aa>.
- ⁶ Rand JH. Antiphospholipid antibody syndrome: New insights on thrombogenic mechanisms: *Am J Med Sci.* 1998;316(2):142–151. <https://doi.org/10.1097/00000441-199808000-00009>.
- ⁷ Tong M, Viall CA, Chamley LW. Antiphospholipid antibodies and the placenta: a systematic review of their in vitro effects and modulation by treatment. *Hum Reprod Update.* 2015;21(1):97–118. <https://doi.org/10.1093/humupd/dmu049>.
- ⁸ Devreese KMJ, de Groot PG, de Laat B, et al. Guidance from the Scientific and Standardization Committee for lupus anticoagulant/antiphospholipid antibodies of the International Society on Thrombosis and Haemostasis: Update of the guidelines for lupus anticoagulant detection and interpretation. *J Thromb Haemost.* 2020;18(11):2828–2839. <https://doi.org/10.1111/jth.15047>.
- ⁹ Devreese KMJ, Ortel TL, Pengo V, de Laat B; Subcommittee on Lupus Anticoagulant/Antiphospholipid Antibodies. Laboratory criteria for antiphospholipid syndrome: Communication from the SSC of the ISTH. *J Thromb Haemost.* 2018;16(4):809–813. <https://doi.org/10.1111/jth.13976>.
- ¹⁰ Giacobbe A, Grasso R, Foti G, Interdonato ML, Mancuso A. Sjögren's syndrome associated with antiphospholipid syndrome and fetal myocardial echogenicity: case report. *J Prenat Med.* 2013;7(2):29–31.
- ¹¹ Flores N, Flores N, Orzuza GI, et al. Neurosjögren and antiphospholipid syndrome: a case report. *J Neurol Sci.* 2015;357:e375. <https://doi.org/10.1016/j.jns.2015.08.1340>.